

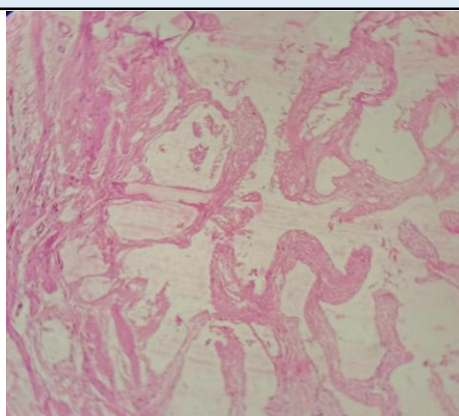
<b>Patient Name</b>	<b>Ms. JYOTI GUPTA</b>	<b>Client Name</b>	Accurate Path (C), Agra	<b>Specimen Received</b>	22/05/2019
<b>Age/Sex</b>	30 Years/Female	<b>Client Code</b>	MolQ1671CM	<b>Specimen Type</b>	Tissue
<b>Patient ID</b>	011905220013	<b>Ref. Doctor</b>		<b>Collection</b>	22/05/2019
<b>Specimen ID</b>	MOLQ/B-927/19			<b>Report Date</b>	25/05/2019

## SURGICAL PATHOLOGY REPORT

### Gall bladder

#### DIAGNOSIS

**CHOLECYSTITIS**



#### SPECIMEN

Gall bladder

#### GROSS

Received 4.5x2.9cm long gall bladder already cut open no stones.

#### Microscopy

Section examined shows ulcerative mucosa and Rokitansky-Aschoff sinus (irregularly shaped tubular structures lined by cuboidal lining epithelium with round to oval nucleus) with fibrocollagenous tissue and inflammatory cells (lymphocytes).

**Note :** All biopsy specimen will be stored for 15 (fifteen) days, block and slides for 5 (five) years only from the time of receipt at the laboratory. No request for any of the above will be entertained after the due date.

#### Reference

- i) Rosai and Ackerman's Surgical Pathology.
- ii) Modern Surgical Pathology.

**Gulshan Yadav, MD**  
Consultant Pathologist