

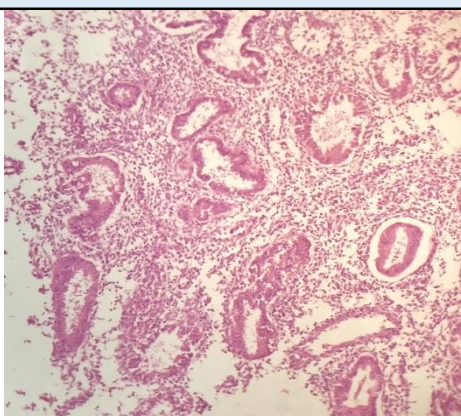
<b>Patient Name</b>	<b>Ms. BABY</b>	<b>Client Name</b>	SBS Diagnostic Centre	<b>Specimen Received</b>	21/05/19
<b>Age/Sex</b>	45 Years/Female	<b>Client Code</b>	MolQ1325CM	<b>Specimen Type</b>	Tissue
<b>Patient ID</b>	011905210346	<b>Ref. Doctor</b>		<b>Collection Date</b>	21/05/19
<b>Specimen ID</b>	MOLQ/B-926/19			<b>Report Date</b>	25/05/2019

## SURGICAL PATHOLOGY REPORT

### Endometrium

#### DIAGNOSIS

### Hyper Progesteronic Effect



#### SPECIMEN

Endometrium

#### GROSS

Received multiple greyish white tissue piece.

#### Microscopy

Section examined shows broken endometrial glands with columnar lining epithelium small round nucleus stroma shows mononuclear inflammatory with blood clot.

No granuloma and no malignant cells seen.

**Note :** All biopsy specimen will be stored for 15 (fifteen)days, block and slides for 5(five) years only from the time of receipt at the laboratory. No request ,for any of the above ,will be entertained after the due date.

#### Reference

- i) Rosai and Ackerman's Surgical Pathology.
- ii) Modern Surgical Pathology.

**Gulshan Yadav, MD**  
Consultant Pathologist