

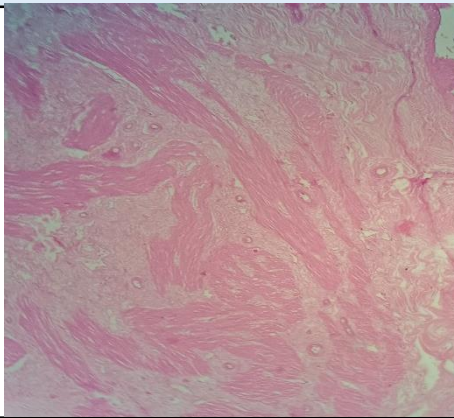
Patient Name	SHAFEEQA	Client Name	Bandipora Collection Centre,	Specimen Received	20/05/2019
Age/Sex	39 YRS/M		Jammu & Kashmir	Specimen Type	Tissue
Patient ID	011905200332	Client Code		Collection Date	20/05/2019
Specimen ID	MOLQ/B-916/19	Ref. Doctor	C.R PORA	Report Date	25/05/2019

SURGICAL PATHOLOGY REPORT

GALL BLADDER.

DIAGNOSIS

CHOLECYSTITIS



SPECIMEN

Gall Bladder.

GROSS

Received 7.5x3.9cm long gall bladder cut section shows no stones.

Microscopy

1. Section examined shows ulcerative mucosa and Rokitansky Aschoff sinus (irregularly shaped tubular structures lined by cuboidal lining epithelium with round to oval nucleus) with fibrocollagenous tissue and inflammatory cells (lymphocytes).

Note : All biopsy specimen will be stored for 15 (fifteen) days, block and slides for 5 (five) years only from the time of receipt at the laboratory. No request, for any of the above, will be entertained after the due date.

Reference

- i) Rosai and Ackerman's Surgical Pathology.
- ii) Modern Surgical Pathology.

Gulshan Yadav, MD
Consultant Pathologist