

आयकर विभाग
INCOME TAX DEPARTMENT



भारत सरकार
GOVT. OF INDIA

MEETU RANI

RAJINDER KUMAR

02/01/1984

Permanent Account Number

BAMPR7287K

Meetu

Signature



20032011


CERTIFICATE OF MEDICAL FITNESS

This is to certify that I have conducted the clinical examination

of Meelin Aggarwal on _____

After reviewing the medical history and on clinical examination it has been found that he/she is

	Tick
<ul style="list-style-type: none"> • Medically Fit 	<input type="checkbox"/>
<ul style="list-style-type: none"> • Fit with restrictions/recommendations <p>Though following restrictions have been revealed, in my opinion, these are not impediments to the job.</p> <p>1. <u>USS = Fluid in P.O.D & Cervicitis</u>.....</p> <p>2. <u>Dyslipidemia</u>.....</p> <p>3. <u>Mild Airway Obstruction</u>.....</p> <p>However the employee should follow the advice/medication that has been communicated to him/her.</p> <p>Review after _____</p>	<input type="checkbox"/>
<ul style="list-style-type: none"> • Currently Unfit. <p>Review after _____ recommended</p>	<input type="checkbox"/>
<ul style="list-style-type: none"> • Unfit 	<input type="checkbox"/>

Dr. 

Medical Officer
The Apollo Clinic, (Location)
Dr. ANIL KUMAR GUPTA
MBBS, MD
Consulting Physician
Regd. No. 7513 (HMC)

This certificate is not meant for medico-legal purposes

उपलब्ध ओ.पी.डी. सुविधाएँ

- हृदय रोग चिकित्सा
(Cardiology)
- बाल एवं भ्रूण रोग चिकित्सा
(Paediatrics & Fetal Medicine)
- बाल रोग चिकित्सा
(Paediatrics)
- स्त्री रोग चिकित्सा
(Gynaecology)
- हड्डी रोग चिकित्सा
(Orthopaedics)
- दन्त चिकित्सा
(Dental Care)
- सामान्य चिकित्सा
(General Physician)
- फिजियोथैरेपी
(Physiotherapy)
- चर्म रोग चिकित्सा
(Dermatology)
- मूत्र रोग चिकित्सा
(Urology)
- गुर्दा रोग चिकित्सा
(Nephrology)

उपलब्ध जाँच

- डायलिसिस (Dialysis)
- अल्ट्रासाउण्ड (Ultrasound)
- ईको (Echo)
- स्ट्रेस ईको (Stress Echo)
- टी.एम.टी. (T.M.T.)
- पी.एफ.टी. (Lung Function Test)
- ई.सी.जी. (E.C.G.)
- ई.ई.जी. (E.E.G.)
- एक्स-रे (X-Ray)
- मैमोग्राफी (Mammography)
- ओ.पी.जी. (Dental X-Ray)
- हॉल्टर टेस्ट (Holter Test)

Ref. No.:

Date:

Name of patient: Mrs. Meenu Aggarwal	Age: 35	M/F: F
Consultant:	Speciality: Package	
MR No : MR007306	Visit No: OP015186	Date: 21-05-2019

HT = 5' 2"
WT = 83 kg
PR = 90/min
BP = 110/66 mmHg
Chest /
Cvs /
Ausc /

Mild Dyslipidemic
Mild in (PO)
Mild Artery const.

Not for Medico Legal Purpose

रून एवं मल-मूत्र की जाँच NABL द्वारा मान्यता प्राप्त MoIQ लैब द्वारा की जाती है।

सम्पर्क सूत्र: 0124-2224102 / 103 / 104 | Mob.: 8683061905, 8683061906

ओ.पी.डी. पर्ची का शुल्क केवल तीन दिन के लिए मान्य रहेगा।

Radiology Report

Name : Mrs. Meetu Aggarwal
Age/Gender : 35 Y/F
Prescribed Doctor : Self

MR No : MR007306
Visit ID : OP015186
Report Date : 21-05-2019 10:33

Ultrasound

USG EXAMINATION : WHOLE ABDOMEN

Liver shows normal shape and size with homogenous echo texture. Intrahepatic biliary radicals are not dilated. No focal lesion is seen. **Portal Vein** shows normal calibre.

Gall bladder shows physiological distension and normal wall thickness. No calculus or mass is seen in the lumen.

CBD is normal in diameter. No calculus is seen

Pancreas is normal in size, shape and echo texture.

Spleen is normal in shape, size and echo texture.

Right kidney show normal shape & size. Cortico-medullary differentiation is maintained. Right kidney show no calculus or hydronephrosis. Right kidney measures 101 x 36mm.

Left kidney show normal shape & size. Cortico-medullary differentiation is maintained. Left kidney show no calculus or hydronephrosis. Left kidney measures 102 x 45mm.

No free fluid is seen in the intra-peritoneal cavity. No evidence of mesenteric lymphadenopathy is seen.

Urinary bladder is normal shape and size with normal wall thickness. No mass or calculus is seen.

Uterus shows normal shape, size and echo texture. No focal lesion is seen. Uterus measures 80 x 42 x 39mm. Endometrial thickness is 5.4mm. **Few small nabothian cysts are seen in cervix.**

Both Ovaries are normal in size, shape and echotexture.

Right ovary measures 29 x 24mm.


Left ovary measures 22 x 23mm.

Bilateral adnexae are clear.

Mild free fluid is seen in POD.

Impression:- Mild free fluid seen in POD.

PLEASE CORRELATE CLINICALLY


Dr. Pawan Joon
MD (Radio- diagnosis)

Radiology Report

Name : Mrs. Meetu Aggarwal
Age/Gender : 35 Y/F
Prescribed Doctor : Self

MR No : MR007306
Visit ID : OP015186
Report Date : 21-05-2019 13:52

X-Ray

X-RAY CHEST PA VIEW

Mid expiratory radiograph.

Bilateral lung fields appears to be clear. No obvious pulmonary parenchymal lesion is seen.


Trachea is central.

Cardiac configuration appears to be normal with normal cardio-thoracic ratio.

Both costo phrenic angles and domes of diaphragm are normal.

Visualized soft tissue and bony thoracic cage appears to be normal.

PLEASE CORRELATE CLINICALLY.


DR. PAWAN JOON
MD (Radio-diagnosis)

rneetu

HR : 56 bpm

Female 35Years

P : 94 ms

PR : 162 ms

QRS : 85 ms

QT/QTc : 436/421 ms

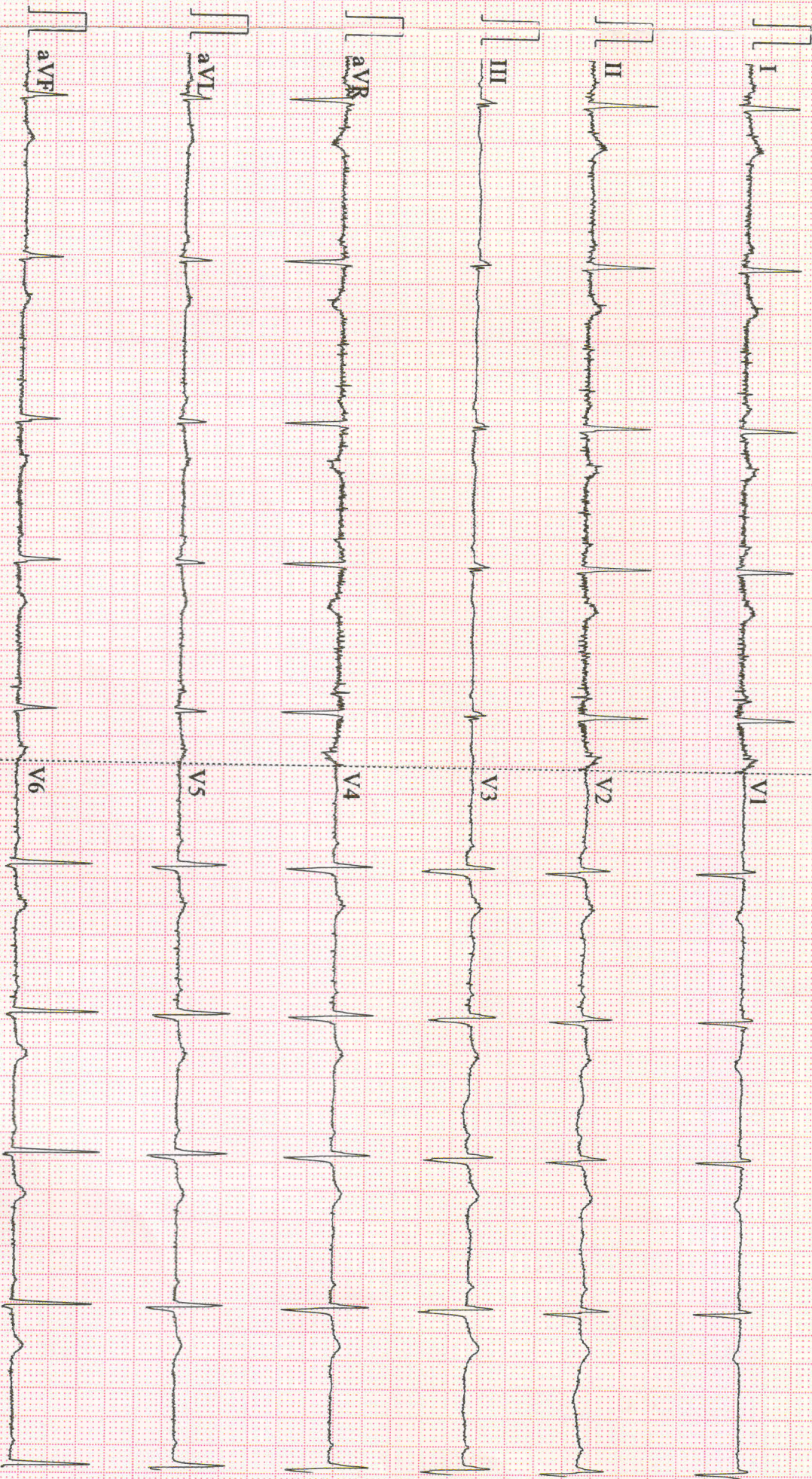
P/QRS/T : 8/40/12 °

RV5/SV1 : 0.881/0.800 mV

Diagnosis Information:

Sinus Bradycardia with Sinus Arrhythmia

Report Confirmed by:



उपलब्ध ओ.पी.डी. सुविधाएँ

- हृदय रोग चिकित्सा
(Cardiology)
- बाल एवं भ्रूण रोग चिकित्सा
(Paediatrics & Fetal Medicine)
- बाल रोग चिकित्सा
(Paediatrics)
- स्त्री रोग चिकित्सा
(Gynaecology)
- हड्डी रोग चिकित्सा
(Orthopaedics)
- दन्त चिकित्सा
(Dental Care)
- सामान्य चिकित्सा
(General Physician)
- फिजियोथैरेपी
(Physiotherapy)
- चर्म रोग चिकित्सा
(Dermatology)
- मूत्र रोग चिकित्सा
(Urology)
- गुर्दा रोग चिकित्सा
(Nephrology)

उपलब्ध जाँच

- डायलिसिस (Dialysis)
- अल्ट्रासाउण्ड (Ultrasound)
- ईको (Echo)
- स्ट्रेस ईको (Stress Echo)
- टी.एम.टी. (T.M.T.)
- पी.एफ.टी. (Lung Function Test)
- ई.सी.जी. (E.C.G.)
- ई.ई.जी. (E.E.G.)
- एक्स-रे (X-Ray)
- मैमोग्राफी (Mammography)
- ओ.पी.जी. (Dental X-Ray)
- हॉल्टर टेस्ट (Holter Test)

Ref. No.:

Date:

Name of patient: Mrs. Meetu Aggarwa	Age: 35	M/F: F
Consultant:	Speciality: Package	
MR No : MR007306	Visit No: OP015186	Date: 21-05-2019

Cy chesant EPID LMP 12/5/19.

P/S. Cy chesant
& bleeda low

Ph - W - AVMS
Bl/E fluid
& tedu

P2

Pap smear
taken for goh

U/S
na
for p.c.s.

24/05/19
[As Parlop - 0
007 7ds

21/05/19
[Cansept - 0
regal pona
12 x 3 dgs

ASD.
as day
10mg
17 x 5ds
as mehoju
40 mg
17 x 5ds
as 10mg
17 x 5ds.

Not for Medico Legal Purpose

खून एवं मल-मूत्र की जाँच NABL द्वारा मान्यता प्राप्त MoIQ लैब द्वारा की जाती है।



विवेकानन्द आरोग्य केन्द्र



466 P, सेक्टर 12 A, नजदीक माधव भवन, गुरुग्राम

(भारत विकास परिषद् महाराणा प्रताप न्यास, गुरुग्राम द्वारा संचालित)

Ref. No.:

ECHO REPORT

Date:

Name : Mrs Meetu Aggarwal	Age : 35 yr -
Date : 21/05/2019	Gender : Female
Clinical Diagnosis : Company Health Check up	Done By: Dr Dixit Garg

M - Mode/ 2-D Description:

Measurements (mm):

	Observed Values		Normal values	
Aortic root diameter	32 mm		20-36 (22mm/M ²)	
Left atrium size	32 mm		19-40 mm	
	End Diastole	Normal values	Endsystole	Normal values
Left Ventricle Size	46 mm	37 -56 mm	30 mm	2.2-4.0 mm
Interventricular Septum	08 mm	6 -12 mm	11 mm	
Posterior wall thickness	08 mm	5 -10 mm	11 mm	
LV ejection fraction (%)	56%		53% - 59%	

DOPPLER VELOCITIES (cm/sec)

<u>Pulmonary valve</u>		<u>Aortic valve</u>	
Max velocity	79 cm/sec	Max velocity	104 cm/sec
Regurgitation	Trace	Regurgitation	None
<u>Mitral valve</u>		<u>Tricuspid valve</u>	
E	84 cm/sec	Max velocity	2.02 m/sec
A	69 cm/sec	Max PG	16 mmHg
E'	08 cm/sec	TAPSE (>1.5)	1.8
Regurgitation	Trace	Regurgitation	Trace



विवेकानन्द आरोग्य केन्द्र

466 P, सेक्टर 12 A, नजदीक माधव भवन, गुरुग्राम

(भारत विकास परिषद् महाराणा प्रताप न्यास, गुरुग्राम द्वारा संचालित)



Ref. No.:.....

Date:.....

Final interpretation :

(HR - 62/min, Rhythm - NSR)

1. No LV RWMA, LVEF 56%.
2. Normal RV systolic function.
3. All Cardiac chamber dimensions normal.
4. Mitral inflow pattern - normal, normal LVEDP.
5. Morphologically normal mitral valve, Trace MR No MS.
6. Morphologically normal aortic valve, No AR, No AS.
7. Morphologically normal Tricuspid valve, Trace TR, Normal PASP.
8. No intra-cardiac clot/ Vegetation / Pericardial effusion seen.
9. IVC normal in size, CVP normal.

Raven

Dr Dixit Garg
DNB Cardiology