

# CERTIFICATE OF MEDICAL FITNESS

This is to certify that I have conducted the clinical examination

of Abhay Kumar on 10/5/19

After reviewing the medical history and on clinical examination it has been found that he/she is

	Tick
<ul style="list-style-type: none"> <li>• Medically Fit</li> </ul>	✓
<ul style="list-style-type: none"> <li>• Fit with restrictions/recommendations</li> </ul> <p>Though following restrictions have been revealed, in my opinion, these are not impediments to the job.</p> <p>1. <u>overweight by 12 kg</u></p> <p>2. <u>NIDDM.</u></p> <p>3. <u>Fatty liver 4-2</u></p> <p>However the employee should follow the advice/medication that has been communicated to him/her. <u>Dr. use type modification follow up by endocrinologist</u></p> <p>Review after _____</p>	
<ul style="list-style-type: none"> <li>• Currently Unfit. Review after _____ recommended</li> <li>• Unfit</li> </ul>	

Dr. Dr. Rakesh Sharma

**Dr. RAKESH SHARMA**  
 Medical Officer (Location) **Substant**  
 The Apollo Clinic  
 Vivekanand Arogya Kendra  
 Gurugram

*This certificate is not meant for medico-legal purposes*

## Radiology Report

Name : Mr. Abhay Kumar  
Age/Gender : 37 Y/M  
Prescribed Doctor : Self

MR No : MR006773  
Visit ID : OP013913  
Report Date : 10-05-2019 11:38

## Ultrasound

### USG EXAMINATION : WHOLE ABDOMEN

**Liver** shows normal shape and size (13.5cm) with mildly increased echogenicity, suggestive of fatty change. Intrahepatic biliary radicals are not dilated. . No focal lesion is seen. **Portal Vein** shows normal calibre.

**Gall bladder** shows physiological distension and normal wall thickness. No calculus or mass is seen in the lumen.

**CBD** is normal in diameter. No calculus is seen

**Pancreas** is normal in size, shape and echo texture.

**Spleen** is normal in shape, size and echo texture.

**Right kidney** show normal shape & size. Cortico-medullary differentiation is maintained. Right kidney show no calculus or hydronephrosis. Right kidney measures 102 x 43mm.

**Left kidney** show normal shape & size. Cortico-medullary differentiation is maintained. Left kidney show no calculus or hydronephrosis. Left kidney measures 105 x 59mm.


No free fluid is seen in the intra-peritoneal cavity. No evidence of mesenteric lymphadenopathy is seen.

**Urinary bladder** is over distended and is normal in shape, size and wall thickness. No mass or calculus is seen.

**Prostate** is normal in shape, size & echo texture. Volume of prostate is 13cc.

**IMP: Fatty liver grade I.**

PLEASE CORRELATE CLINICALLY.

  
Dr. Pawan Joon  
MD ( Radio- diagnosis)

## ECHO REPORT

NAME	MR. ABHAY KUMAR	AGE/SEX	37/M
UHD No.	006773	HOSPITAL NO.	OPD
REF. BY	HEALTH CHECK UP	DATE	10.05.2019

PROCEDURES : M-MODE / 2D / DOPPLER / COLOUR / CONTRAST B.B.A. M2  
MEASUREMENTS :

		NORMALS
Aortic Root Diameter	2.4	2.0-3.7 cm < 2.2 cm/M2
Aortic Valve Opening		1.5-2.6 cm
Right Ventricular Dimension		0.7-2.6 cm < 1.4 cm/M2
Right Ventricular Thickness		0.3-0.9 cm
Left Atrial Dimension	2.9	1.9-4.0 cm < 2.2 cm/M2
Left Ventricular ED Dimension	3.6	3.7-5.6 cm < 3.2 cm/M2
Left Ventricular ES Dimension	4.6	2.2-4.0 cm
Interventricular Septal Thickness	1.0 ED ES	0.6-1.2 cm
Left Vent PW Thickness	0.8 ED ES	0.5-1.0 cm
IVS / LVPW		

### INDICES OF LEFT VENT. FUNCTION

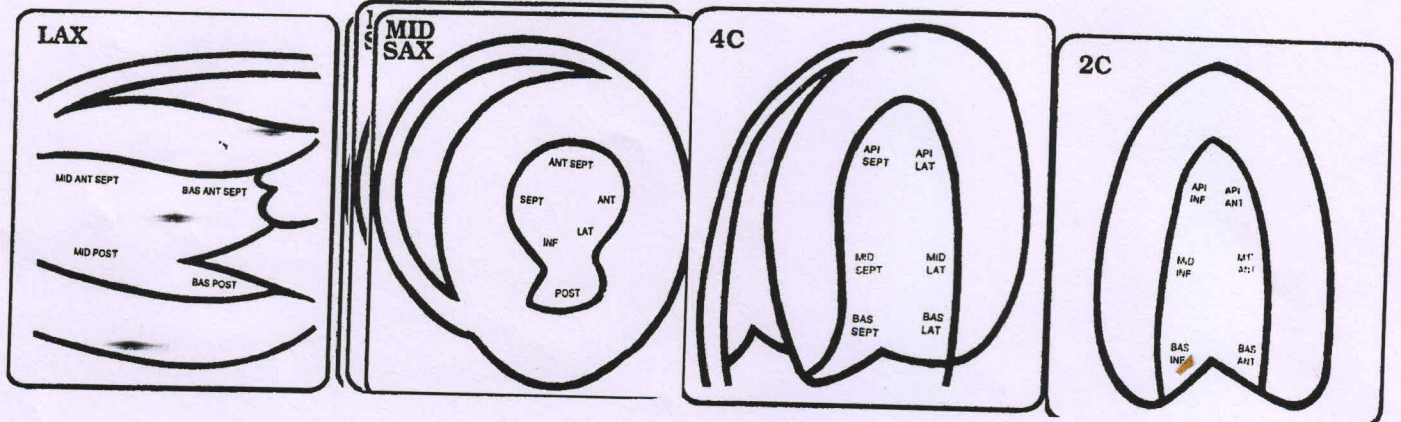
Mitral E-Septal separation		<0.9 cm
Minor axis		24.42%
LV Ejection Fraction	60%	55-65%

### IMAGING:

M-Mode examination revealed normal movement of both mitral leaflets during diastole. No SAM or mitral valve prolapse is seen. Aortic cusps are not thickened and closure line is central. Tricuspid valve is normal. Pulmonary valve is normal. Aortic root is normal in size. Dimension of left atrium and left ventricle are normal. No LVH present.

2-D imaging in PLAX, SAX and apical views revealed a normal sized left ventricle. Movement of septum, inferior, anterior, posterior and lateral walls is normal. Global LVEF is 60%. Mitral valve opening is normal. No evidence of mitral valve prolapse is seen. Aortic valve has three cusps and its opening is not restricted. Tricuspid valve leaflets move normally. Pulmonary valve is normal. Interatrial and interventricular septa are intact. No intracardiac mass or thrombus is seen. No pericardial pathology is observed.

## LV WALL MOTION



## DOPPLER

MV	E = cm/sec A = cm/sec	MR	Nil
AV	cm/sec	AR	Nil
TV	cm/sec	TR	Nil
PV	cm/sec	PR	Nil

## COLOUR FLOW

Normal colour flow

## FINAL DIAGNOSIS:

2D Colour Doppler Exam of Mr. Abhay kumar revealed:

1. No regional wall motion abnormalities seen in resting state. LVEF - 60%.
2. No LVH. All cardiac chambers dimensions are normal.
3. All valves are normal.
4. Normal left ventricular function.
5. No intracardiac mass or thrombus
6. No pericardial pathology seen. No clot /veg seen.

DR. ASHISH GUPTA

**Dr. ASHISH GUPTA**  
 MBBS, MD(Medicine), DM(Cardiology)  
 Consultant Cardiology  
 Vivekanand Arogya Kendra  
 Regn. No. HMC-10365

## Radiology Report

Name : Mr. Abhay Kumar  
Age/Gender : 37 Y/M  
Prescribed Doctor : Self

MR No : MR006773  
Visit ID : OP013913  
Report Date : 10-05-2019 16:01

## X-Ray

### X-RAY CHEST PA VIEW

Bilateral lung fields appears to be clear. No obvious pulmonary parenchymal lesion is seen.

Trachea is central.


Cardiac configuration appears to be normal with normal cardio-thoracic ratio.

Both costo phrenic angles and domes of diaphragm are normal.

Visualized soft tissue and bony thoracic cage appears to be normal.

*Scoliosis of the thoracic spine is noted with convexity to words right side.*

PLEASE CORRELATE CLINICALLY.

  
DR. PAWAN JOON  
MD (Radio-diagnosis)

### उपलब्ध ओ.पी.डी. सुविधाएँ

- हृदय रोग चिकित्सा  
(Cardiology)
- बाल एवं भ्रूण रोग चिकित्सा  
(Paediatrics & Fetal Medicine)
- बाल रोग चिकित्सा  
(Paediatrics)
- स्त्री रोग चिकित्सा  
(Gynaecology)
- हड्डी रोग चिकित्सा  
(Orthopaedics)
- दन्त चिकित्सा  
(Dental Care)
- सामान्य चिकित्सा  
(General Physician)
- फिजियोथैरेपी  
(Physiotherapy)
- चर्म रोग चिकित्सा  
(Dermatology)
- मूत्र रोग चिकित्सा  
(Urology)
- गुर्दा रोग चिकित्सा  
(Nephrology)

### उपलब्ध जाँच

- डायलिसिस (Dialysis)
- अल्ट्रासाउण्ड (Ultrasound)
- ईको (Echo)
- स्ट्रेस ईको (Stress Echo)
- टी.एम.टी. (T.M.T.)
- पी.एफ.टी. (Lung Function Test)
- ई.सी.जी. (E.C.G.)
- ई.ई.जी. (E.E.G.)
- एक्स-रे (X-Ray)
- मैमोग्राफी (Mammography)
- ओ.पी.जी. (Dental X-Ray)
- हॉल्टर टेस्ट (Holter Test)

Ref. No.:.....

Date:.....

Name of patient: Mr. Abhay Kumar	Age: 37	M/F: M
Consultant:	Speciality: Package	
MR No : MR006773	Visit No: OP013913	Date: 10-05-2019

Ht/M - 170 cm  
Wt/M - 82 kg  
BMI - 28.37  
B.P. - 112/82 mm of Hg  
Pulse - 80/min, regular

G/E.  
Internal  
Palp - Nil  
Spleen  
Lymphadenopathy - Nil

vision:  
distant - (R) 6/6  
(L) 6/6  
near - N-5 (B) eye

ENT -  
Throat - NNG  
Nose - NNG  
Ear - (B) TMJ intact  
& normal.

Syst/Easm:  
chest - clinically NNG

Abdomen: Soft - Liver & spleen not palpable.

F/M - Father had DM -  
died of cerebral stroke

H/O of Diabetes Mellitus -  
was on medication  
for DM in 2016

No H/O admission of  
alcohol or tobacco  
abuse.

Observation:  
① overweight by  
12kg  
② ? NIDDM

Pharmf.:

Not for Medico Legal Purpose

खून एवं मल-मूत्र की जाँच NABL द्वारा मान्यता प्राप्त MolQ लैब द्वारा की जाती है।

सम्पर्क सूत्र: 0124-2224102 / 103 / 104 | Mob.: 8683061905, 8683061906

ओ.पी.डी. पर्ची का शुल्क केवल तीन दिन के लिए मान्य रहेगा।

15/5/19

## Investigation reports:

- ① HbA1c — ~~6.8~~ 6.8
- ② Blood sugar —  $\begin{cases} < 125 \text{ mg\%} \\ < 231 \text{ mg\%} \end{cases}$
- ③ CBC — WNL
- ④ Blood Urea — WNL
- ⑤ Blood Uric acid — WNL
- ⑥ S. creatinine — WNL
- ⑦ LFT — mildly deranged
- ⑧ S. lipid profile — WNL
- ⑨ PSA — WNL
- ⑩ TFT — WNL
- ⑪ E.G. of urine — WNL
- ⑫ X-ray chest — WNL
- ⑬ U.S. Abdomen — Fatty liver G-2
- ⑭ Echo — AFM

## Observations:

- ① Overweight by 12kg
- ② NIDDM.
- ③ Fatty liver G-2

→

- ① Life style modification
  - Regular morning walk
  - 16hr kcal diet
  - Avoid simple sugars
  - Small & frequent meals
  - Blood sugar monitoring weekly
  - HbA1c every 3 months
  - Serum lipid profile & salts

- ② Follow up by medical specialist / Endocrinologist

**Dr. RAKESH SHARMA**  
M.B.B.S. (Sr. Consultant)  
Vivekanand Arogya Kendra  
Gurugram

*Dr. Rakesh Sharma*

**BANK OF AMERICA HEALTH CHECK-UP**  
**VOUCHER**

**AT**

**APOLLO CLINICS**

This voucher and the information set out herein (including any personal data) are provided to you (Employee) so you can avail the Health Check-Up at Service Provider. Bank of America, WTW & Vipul do not provide any personal data to Service Provider. If you choose to provide your personal data to Service Provider to avail the Health Check-Up, Service Provider will be accountable to you directly for its collection and use of your personal data in accordance with applicable law.

Service Provider will examine the bearer of this letter according to the following details:

Voucher Code	<b>GBS HCU GGN/2019/3797</b>		
Name of Beneficiary	Abhay Kumar		
Optional Test(s)	No		
Package	Bank of America Comprehensive Package		
Date of Check-up	10-May-19	Voucher Issue Date	03 MAY,19
Reporting Time	8.30 AM	Voucher Validity	Until the date of appointment mentioned on the voucher*
Centre Name & Address	Molecular Quest Healthcare Pvt Ltd. 466P Sector 12A near madhav bhawan, Gurugram, Haryana 122001		
<b>*Remarks:</b>			
<ul style="list-style-type: none"><li>• This voucher will be issued once only and no reissuance upon lost or expiry.</li><li>• It will be collected by the clinic and cannot be re-used.</li><li>• This Voucher is neither transferable or nor convertible to other monetary means.</li></ul>			

**Important Instructions:**

- Employee needs to carry this health check-up Voucher, Company ID card and Govt. photo ID proof for identification at the time of health check-up.
- Health Check-Up may take 4 – 5 hrs for completion on week days & 5 – 6 hrs on Saturdays
- Health Check Up report would be available within 48 hours of the check-up done. Employee should collect the report directly from the hospital help desk & can avail the consultation.



**Instructions to undergo Health Check:**

- Please ensure you are on complete fasting for 10-To-12-Hours prior to check.
- During fasting time do not take any kind of medication, alcohol, cigarettes, tobacco or any other liquids (except Water) in the morning.
- Kindly carry your medication, if taking any.
- Bring urine sample in a container if possible (Otherwise, containers are available at the Health Check center).
- Please bring all your medical prescriptions and previous health medical records with you.
- Kindly inform the health check reception in case if you have a history of diabetes and cardiac problems.

**For Women:**

- Pregnant Women or those suspecting are advised not to undergo any X-Ray test.
- It is advisable not to undergo any Health Check during menstrual cycle.

Abhay  
Kumar



BA Continuum India Pvt. Ltd.

Abhay Kumar

भारत सरकार  
Government of India

अभय कुमार  
Abhay Kumar

जन्म तिथि / DOB : 01/03/1983  
पुरुष / Male

9224 6238 3414

आधार - आम आदमी का अधिकार



*Abhay Kumar*

भारतीय विशिष्ट पहचान प्राधिकरण  
Unique Identification Authority of India

पता: आत्मज: विश्वनाथ प्रसाद  
सिरवाताव, हरखुवा टोला वाडे न 22,  
गोपालगंज, गोपालगंज, बिहार,  
841428

Address: S/O: Vishwanath Prasad  
Sirwastav, HARKHUWA TOLA WARD  
NO.22, Gopalganj, Gopalganj, Bihar,  
841428

9224 6238 3414

1947  
1800 300 1947

help@uidai.gov.in

www.uidai.gov.in