

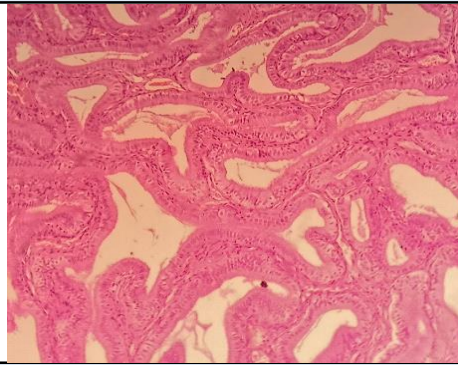
Patient Name	RONAK RO ARIN	Client Name	Bandipora Collection Centre,	Specimen Received	15/05/19
Age/Sex	16 YRS/F		Jammu & Kashmir	Specimen Type	Tissue
Patient ID	011905150484	Client Code		Collection Date	15/05/19
Specimen ID	MOLQ/B-878/19	Ref. Doctor		Report Date	22/05/19

SURGICAL PATHOLOGY REPORT

Gall bladder

DIAGNOSIS

CHOLECYSTITIS WITH CHOLELITHIASIS



SPECIMEN

Gall bladder

GROSS

Received 6.5x3.1cm long autolyzed gall bladder without stones.

Microscopy

Section examined shows ulcerative mucosa and Rokitansky-Aschoff sinuses (irregularly shaped tubular structures lined by cuboidal lining epithelium with round to oval nucleus) with fibro collagenous tissue and inflammatory cells (lymphocytes).

Note : All biopsy specimen will be stored for 15 (fifteen) days, block and slides for 5 (five) years only from the time of receipt at the laboratory. No request, for any of the above, will be entertained after the due date.

Reference

- i) Rosai and Ackerman's Surgical Pathology.
- ii) Modern Surgical Pathology.

Gulshan Yadav, MD
Consultant Pathologist