

## CERTIFICATE OF MEDICAL FITNESS

This is to certify that I have conducted the clinical examination

of Nitin Nair on 4/5/2019

After reviewing the medical history and on clinical examination it has been found that he/she is

	Tick
<ul style="list-style-type: none"> <li>• Medically Fit</li> </ul>	<input type="checkbox"/>
<ul style="list-style-type: none"> <li>• Fit with restrictions/recommendations</li> </ul> <p>Though following restrictions have been revealed, in my opinion, these are not impediments to the job.</p> <p>1. <u>less - Fatty Liver Gr I</u></p> <p>2. <u>Dyslipidaemia</u></p> <p>3. <u>Raised TSH</u></p> <p>However the employee should follow the advice/medication that has been communicated to him/her.</p> <p>Review after <u>6m</u></p>	<input checked="" type="checkbox"/>
<ul style="list-style-type: none"> <li>• Currently Unfit. Review after _____ recommended</li> <li>• Unfit</li> </ul>	<input type="checkbox"/>

Dr. \_\_\_\_\_

*(Signature)*  
**Dr. ASHOK K. GUPTA**  
 Medical Officer MBBS, MD  
 Consulting Physician  
 The Apollo Clinic, (Location)  
 Regd. No. 7019 (Karnataka)

*This certificate is not meant for medico-legal purposes*

## VIVEKANAND AROGY KENDRA HOSPITAL

**Patient Details**      Date: 04-May-19      Time: 1:17:16 PM  
**Name:** Nitin Nair    ID: 006465  
**Age:** 29 y      **Sex:** M      **Height:** 168 cms      **Weight:** 65 Kgs  
**Clinical History:** Nothing significant

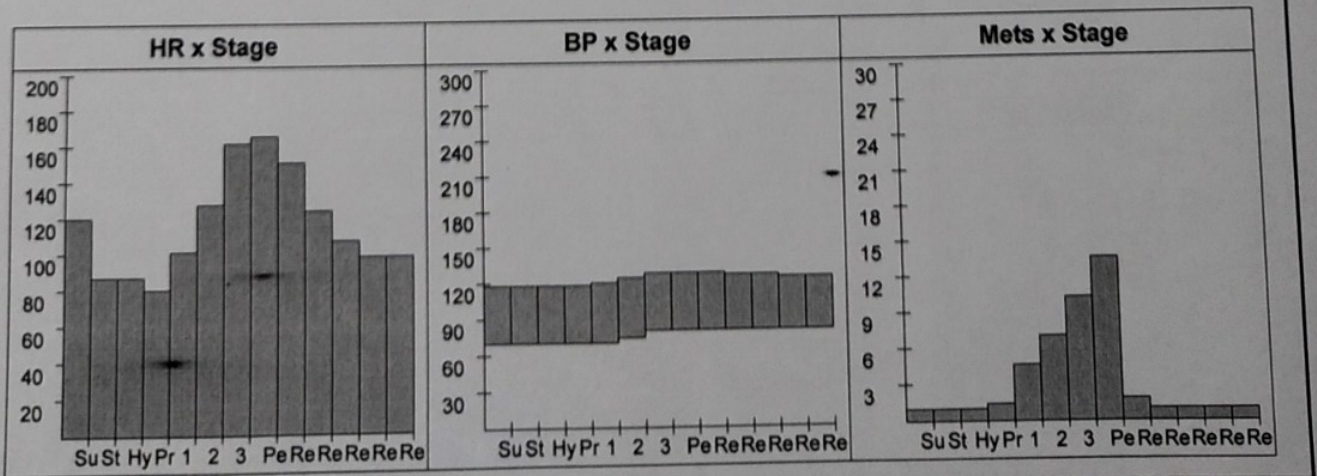
**Medications:** nil

### Test Details

**Protocol:** Bruce      **Pr.MHR:** 191 bpm      **THR:** 162 (85 % of Pr.MHR) bpm  
**Total Exec. Time:** 9 m 17 s      **Max. HR:** 165 (86% of Pr.MHR) bpm      **Max. Mets:** 13.50  
**Max. BP:** 128 / 80 mmHg      **Max. BP x HR:** 21120 mmHg/min      **Min. BP x HR:** 6090 mmHg/min  
**Test Termination Criteria:** THR achieved

### Protocol Details

Stage Name	Stage Time (min : sec)	Mets	Speed (mph)	Grade (%)	Heart Rate (bpm)	Max. BP (mm/Hg)	Max. ST Level (mm)	Max. ST Slope (mV/s)
Supine	0 : 22	1.0	0	0	120	118 / 70	-2.12 I	5.31 aVF
Standing	0 : 6	1.0	0	0	87	118 / 70	-1.91 aVL	5.31 aVF
Hyperventilation	0 : 12	1.0	0	0	87	118 / 70	-0.64 aVR	3.54 III
1	3 : 0	4.6	1.7	10	101	120 / 70	-4.88 III	5.66 III
2	3 : 0	7.0	2.5	12	127	124 / 74	-5.94 I	5.66 I
3	3 : 0	10.2	3.4	14	161	128 / 80	-1.49 III	4.60 II
Peak Ex	0 : 17	13.5	4.2	16	165	128 / 80	-1.70 III	4.60 II
Recovery(1)	1 : 0	1.8	1	0	150	128 / 80	-4.67 III	5.31 V2
Recovery(2)	1 : 0	1.0	0	0	123	126 / 80	-2.55 aVR	5.66 V2
Recovery(3)	1 : 0	1.0	0	0	106	126 / 80	-2.55 aVR	4.60 II
Recovery(4)	1 : 0	1.0	0	0	97	124 / 80	-1.70 aVR	3.54 II
Recovery(5)	0 : 5	1.0	0	0	97	124 / 80	-0.64 aVR	2.12 V4





## VIVEKANAND AROGY KENDRA HOSPITAL

### Patient Details

Date: 04-May-19 Time: 1:17:16 PM  
Name: Nitin Nair ID: 006465 Height: 168 cms Weight: 65 Kgs  
Age: 29 y Sex: M

### Interpretation

No significant ST-T changes during TMT study.  
TMT is negative for reversible myocardial ischaemia with good exercise capacity.  
Correlate clinically

*[Handwritten signature]*

Ref. Doctor: -----

Doctor: -----

( Summary Report edited by user )



# विवेकानन्द आरोग्य केन्द्र

466 P, सेक्टर 12 A, नजदीक माधव भवन, गुरुग्राम  
(भारत विकास परिषद् महाराणा प्रताप न्यास, गुरुग्राम द्वारा संवाहित)



## उपलब्ध ओ.पी.डी. सुविधाएँ

- हृदय रोग चिकित्सा (Cardiology)
- बाल एवं भ्रूण रोग चिकित्सा (Paediatrics & Fetal Medicine)
- बाल रोग चिकित्सा (Paediatrics)
- स्त्री रोग चिकित्सा (Gynaecology)
- हड्डी रोग चिकित्सा (Orthopaedics)
- दन्त चिकित्सा (Dental Care)
- सामान्य चिकित्सा (General Physician)
- फिजियोथैरेपी (Physiotherapy)
- चर्म रोग चिकित्सा (Dermatology)
- मूत्र रोग चिकित्सा (Urology)
- गुर्दा रोग चिकित्सा (Nephrology)

## उपलब्ध जाँच

- डायलिसिस (Dialysis)
- अल्ट्रासाउण्ड (Ultrasound)
- ईको (Echo)
- स्ट्रेस ईको (Stress Echo)
- टी.एम.टी. (T.M.T.)
- पी.एफ.टी. (Lung Function Test)
- ई.सी.जी. (E.C.G.)
- ई.ई.जी. (E.E.G.)
- एक्स-रे (X-Ray)
- मैमोग्राफी (Mammography)
- ओ.पी.जी. (Dental X-Ray)
- हॉल्टर टेस्ट (Holter Test)

Ref. No.:.....

Date:.....

Name of patient: Mr. Nitin Nair	Age: 29	M/F: M
Consultant:	Speciality: Package	
MR No : MR006465	Visit No: OP013250	Date: 04-05-2019

Loose stool.

Ht 172 cm

Wt 66.5 kg

R 84 / min

Bp 111 / 74 mmHg

Chest /  
Abd /  
CVS /

Tab Ornot

1 Tab 1st 2nd

Aug 5

Not for Medico Legal Purpose

खून एवं मल-मूत्र की जाँच NABL द्वारा मान्यता प्राप्त MoIQ लैब द्वारा की जाती है।

सम्पर्क सूत्र: 0124-2224102 / 103 / 104 | Mob.: 8683061905, 8683061906

ओपीडी पर्ची का शुल्क केवल तीन दिन के लिए मान्य रहेगा।





# विवेकानन्द आरोग्य केन्द्र

डायग्नोस्टिक, डायग्नोस्टिक एवं ओपीडी  
भारत विकास परिषद्, महाराष्ट्र प्रजापद न्यास द्वारा संचालित



## Radiology Report

Name : Mr. Nitin Nair  
Age/Gender : 29 Y/M  
Prescribed Doctor : Self

MR No : MR006465  
Visit ID : OP013250  
Report Date : 04-05-2019 14:30

## X-Ray

### X-RAY CHEST PA VIEW

#### Rotated radiograph.

Soft tissue and bony thoracic cage are normal.

Trachea is central.


Cardiac configuration is normal with normal cardio-thoracic ratio.

Pulmonary vasculature is within normal limits.

Both costo phrenic angles and domes of diaphragm are normal.

No pulmonary parenchymal lesion is seen.

PLEASE CORRELATE CLINICALLY.

  
Dr. Pawan Joon  
MD (Radiologist)



# विवेकानन्द आरोग्य केन्द्र

डायग्नोस्टिक एवं ओ.पी.डी.  
भारत विकास परिषद्, महाराणा प्रताप न्यास ट्रस्ट संवाहित



## Radiology Report

Name : Mr. Nitin Nair  
Age/Gender : 29 Y/M  
Prescribed Doctor : Self

MR No : MR006465  
Visit ID : OP013250  
Report Date : 04-05-2019 11:41

## Ultrasound

### USG EXAMINATION : WHOLE ABDOMEN

**Liver** shows normal shape and size (131mm) with **mildly increased echogenicity, suggestive of fatty change**. Intrahepatic biliary radicals are not dilated. No focal lesion is seen. **Portal Vein** shows normal calibre.

**Gall bladder** shows physiological distension and normal wall thickness. No calculus or mass is seen in the lumen.

**CBD** is normal in diameter. No calculus is seen

**Pancreas** is normal in size, shape and echo texture.

**Spleen** is normal in shape, size and echo texture.

**Right kidney** show normal shape & size. Cortico-medullary differentiation is maintained. Right kidney show no calculus or hydronephrosis. Right kidney measures 108 x 39m.

**Left kidney** show normal shape & size. Cortico-medullary upper differentiation is maintained. Left kidney show no calculus or hydronephrosis. Left kidney measures 105 x 47m.


No free fluid is seen in the intra-peritoneal cavity. No evidence of mesenteric lymphadenopathy is seen.

**Urinary bladder** is over distended and is normal in shape, size and wall thickness. No mass or calculus is seen.

**Prostate** is normal in shape, size & echo texture. Volume of prostate is 13.1cc.

**IMP: Fatty liver grade I.**

PLEASE CORRELATE CLINICALLY.

  
Dr. Pawan Joon  
MD ( Radio- diagnosis)