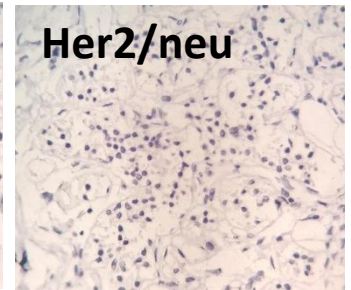
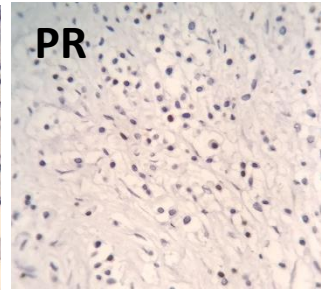
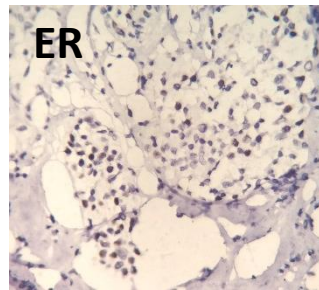
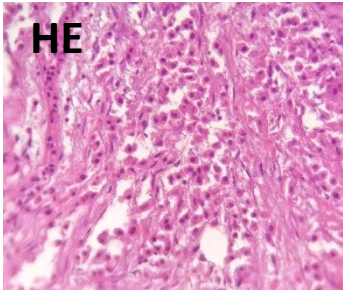


Patient Name	Mr Rajkumari	Client Name	Final Diagnostics Path	Specimen Received	12-May-2019
Age/Sex	50/F		Lab, Agra	Specimen Type	Block
Patient ID	011905120019	Client Code		Collection Date	12-May-2019
Specimen ID	MOLQ/IHC-28052019	Ref. Doctor		Report Date	21-May-2019

SURGICAL PATHOLOGY REPORT

DIAGNOSIS

Estrogen Receptor α - Positive
Progesterone Receptor-Positive
Her-2/neu-Negative



Microscopy:

Estrogen Receptor α (ER)

-% Cells immunoreactive – 04%
 Intensity- +1 (Mild Staining)
 Internal control-Positive
 Interpretation-Positive

Progesterone Receptor (PR)

-% Cells immunoreactive – 05%
 Intensity- +2 (Moderate Staining)
 Internal control-Positive
 Interpretation-Positive

Her-2/neu

-% Cells immunoreactive – 00%
 Intensity- 0
 Internal control-Positive
 Interpretation-Negative

SPECIMEN

Received FFPE block labelled as B-844-19 E

Gulshan Yadav, MD
Consultant Pathologist

Reference

- i) Rosai and Ackerman's Surgical Pathology.
- ii) Modern Surgical Pathology.