

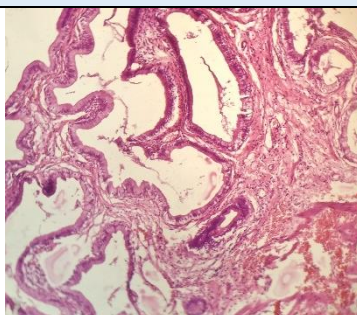
Patient Name	Mrs. SHAMEEMA	Client Name	Patients Care Clinical Laboratory	Specimen Received	11-May-2019
	9014		Jammu & Kashmir	Specimen Type	Tissue
Age/Sex	40Years/F	Client Code	MoIQ1839P	Collection Date	11-May-2019
Patient ID	011905100150	Ref. Doctor	LIFE CARE DOORU	Report Date	18-May-2019
Specimen ID	MOLQ/B-853/19				

SURGICAL PATHOLOGY REPORT

Gall bladder

DIAGNOSIS

CHOLECYSTITIS AND CHOLELITHIASIS



SPECIMEN

Gall bladder

GROSS

Received 7x2.3 cm long gall bladder. Cut section shows stones.

Microscopy

- Section examined shows ulcerative mucosa and rokitansky aschoff sinus (irregularly shaped tubular structures lined by cuboidal lining epithelium with round to oval nucleus) with fibro collagenous tissue and inflammatory cells (lymphocytes).

Note : All biopsy specimen will be stored for 15 (fifteen)days, block and slides for 5(five) years only from the time of receipt at the laboratory. No request ,for any of the above ,will be entertained after the due date.

Reference

- Rosai and Ackerman's Surgical Pathology.
- Modern Surgical Pathology.

Gulshan Yadav, MD
Consultant Pathologist