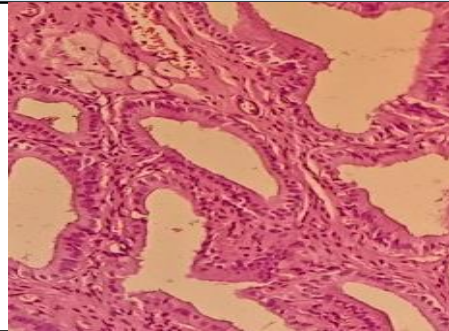


<b>Patient Name</b>	<b>Ms. GUDI 208 MANIGA</b>	<b>Client Name</b>	Apollo Laboratories CC,	<b>Specimen Received</b>	07/05/19
<b>Age/Sex</b>	50 Years/Female		Jammu & Kashmir	<b>Specimen Type</b>	Tissue
<b>Patient ID</b>	011905070135	<b>Client Code</b>	MolQ1961P	<b>Collection Date</b>	07/05/19
<b>Specimen ID</b>	MOLQ/B-811-19	<b>ReferBy</b>	PROF G M SHEIKH MS	<b>Report Date</b>	14/05/19

## SURGICAL PATHOLOGY REPORT

### Gall Bladder

#### CHOLECYSTITIS



#### SPECIMEN

Gall Bladder

#### GROSS

Received 7.7x3.3 cm long gall bladder already cut open without stones.

#### Microscopy

Section examined shows ulcerative mucosa and Rokitansky-Aschoff sinuses (irregularly shaped tubular structures lined by cuboidal lining epithelium with round to oval nucleus) with fibro collagenous tissue and inflammatory cells (lymphocytes).

**Note :** All biopsy specimen will be stored for 15 (fifteen) days, block and slides for 5 (five) years only from the time of receipt at the laboratory. No request for any of the above, will be entertained after the due date.

#### Reference

- i) Rosai and Ackerman's Surgical Pathology.
- ii) Modern Surgical Pathology.

**Gulshan Yadav, MD**  
Consultant Pathologist