

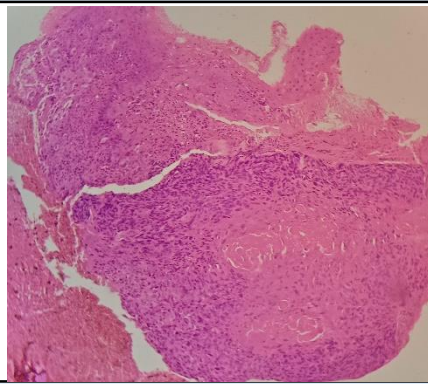
Patient Name	Ms. REHMATI BNL	Client Name	Patients Care Clinical Laboratory	Specimen Received	07-May-2019
Age/Sex	47 Years/Female		Jammu & Kashmir	Specimen Type	Tissue
Patient ID	011905060392	Client Code	MolQ1839P	Collection Date	07-May-2019
Specimen ID	MOLQ/B-815-19	Ref. Doctor	C/O SHOWKAT	Report Date	14-May-2019

SURGICAL PATHOLOGY REPORT

Esophageal Growth

DIAGNOSIS

WELL TO MODERATELY DIFFERENTIATED SQUAMOUS CELL CARCINOMA.



SPECIMEN

Esophageal Growth

GROSS

Received multiple greyish white tissue piece.

Microscopy

1. Section examined shows squamous epithelial lining with breach in the continuity of basement membrane and tumor epithelial cells invading the connective tissue stroma in form of islands and cords.
2. Stroma shows fibrocollagenous tissue and inflammatory cells.

Note : All biopsy specimen will be stored for 15 (fifteen) days, block and slides for 5 (five) years only from the time of receipt at the laboratory. No request ,for any of the above ,will be entertained after the due date.

Reference

- i) Rosai and Ackerman's Surgical Pathology.
- ii) Modern Surgical Pathology.

Gulshan Yadav, MD
Consultant Pathologist