

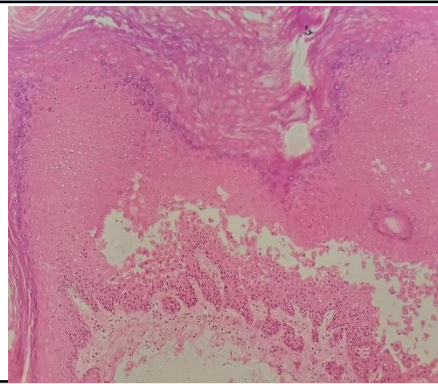
Patient Name	Mr. BASHRAT KGN	Client Name	Tantray Labs,	Specimen Received	05-May-2019
Age/Sex	19 Years/Male		Jammu & Kashmir	Specimen Type	Tissue
Patient ID	011905050325	Client Code	MolQ1849P	Collection Date	05-May-2019
Specimen ID	MOLQ/B-796-19	Ref. Doctor		Report Date	14-May-2019

SURGICAL PATHOLOGY REPORT

Buttock Scraping

DIAGNOSIS

VIRAL INFECTED LESION



SPECIMEN

Buttock Scraping

GROSS

Received 1X2 cm greyish white tissue piece.

Microscopy

- Section examined shows squamous lining epithelium with hyperkeratosis and parakeratosis with koilocytic changes with inflammatory cells. No granuloma and no malignant cells seen.

Note : All biopsy specimen will be stored for 15 (fifteen)days, block and slides for 5(five) years only from the time of receipt at the laboratory. No request ,for any of the above ,will be entertained after the due date.

Reference

- Rosai and Ackerman's Surgical Pathology.
- Modern Surgical Pathology.

Gulshan Yadav, MD
Consultant Pathologist