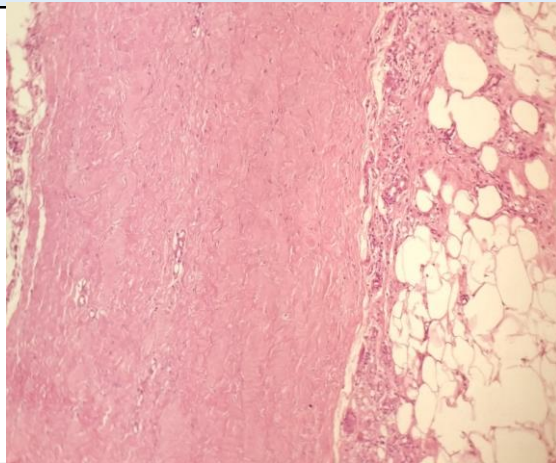


| | | | | | |
|---------------------|-------------------------------|--------------------|--|--------------------------|----------|
| Patient Name | FIRDOUSA W.O BASHIR AH /DOORU | Client Name | Patients Care Clinical Laboratory, Jammu & Kashmir | Specimen Received | 05/05/19 |
| Age/Sex | 32 YRS/F | Code | | Specimen Type | Tissue |
| Patient ID | 011905040392 | Ref. Doctor | CARE DIAG | Collection Date | 05/05/19 |
| Specimen ID | MOLQ/B-792-19 | | | Report Date | 13/05/19 |

SURGICAL PATHOLOGY REPORT
Foreign Body Granuloma (Post infected)

DIAGNOSIS

FOREIGN BODY TYPE OF GRANULOMA



SPECIMEN

Foreign Body Granuloma (Post infected)

GROSS

Received 4x3 cm greyish white tissue piece.

Microscopy

Section examined shows fibrocollagenous tissue, blood vessels, mature adipose cells, mononuclear inflammatory cells, multinucleated giant cells, mononuclear inflammatory cells. No malignant cells and no granuloma seen.

Note : All biopsy specimen will be stored for 15 (fifteen)days, block and slides for 5(five) years only from the time of receipt at the laboratory. No request ,for any of the above ,will be entertained after the due date.

Reference

- i) Rosai and Ackerman's Surgical Pathology.
- ii) Modern Surgical Pathology.

Gulshan Yadav, MD
Consultant Pathologist