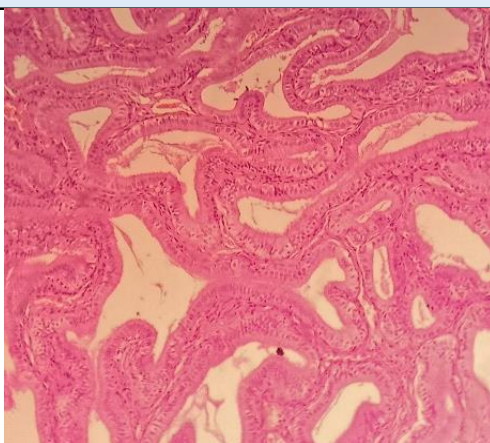


<b>Patient Name</b>	<b>Mr. GHULAM RASOOL</b>	<b>Client Name</b>	Apollo Laboratories CC,	<b>Specimen Received</b>	03/05/19
<b>Age/Sex</b>	58 Years/Male		Jammu & Kashmir	<b>Specimen Type</b>	Tissue
<b>Patient ID</b>	011905020084	<b>Client Code</b>	MolQ1961P	<b>Collection Date</b>	03/05/19
<b>Specimen ID</b>	MOLQ/B-766/19	<b>ReferBy</b>	DR S M MAQBOOL MS	<b>Report Date</b>	06/05/19

## SURGICAL PATHOLOGY REPORT

### Gall Bladder

#### CHOLECYSTITIS WITH CHOLELITHIASIS



#### SPECIMEN

Gall Bladder

#### GROSS

Received 6.3x2.2cm long gall bladder already cut open.

#### Microscopy

Section examined shows ulcerative mucosa and Rokitansky Aschoff sinus (irregularly shaped tubular structures lined by cuboidal lining epithelium with round to oval nucleus) with fibro collagenous tissue and inflammatory cells (lymphocytes).

**Note :** All biopsy specimen will be stored for 15 (fifteen) days, block and slides for 5 (five) years only from the time of receipt at the laboratory. No request for any of the above, will be entertained after the due date.

#### Reference

- i) Rosai and Ackerman's Surgical Pathology.
- ii) Modern Surgical Pathology.

**Gulshan Yadav, MD**  
Consultant Pathologist