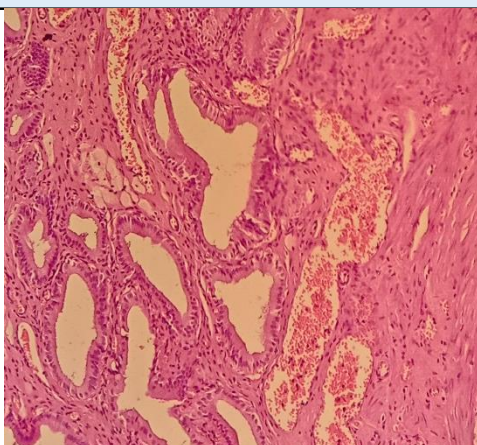


Patient Name	Ms. HAFEEZA	Client Name	Patients Care Clinical	Specimen Received	05/05/19
Age/Sex	50 Years/Female		Laboratory, Jammu & Kashmir	Specimen Type	Tissue
Patient ID	011905040393	Client Code	MolQ1839P	Collection Date	05/05/19
Specimen ID	MOLQ/B-793/19			Report Date	10/05/19

SURGICAL PATHOLOGY REPORT

Gall Bladder

CHOLECYSTITIS



SPECIMEN

Gall Bladder

GROSS

Received 6.2x3.2cm long gall bladder already cut open no stone.

Microscopy

Section examined shows ulcerative mucosa and Rokitansky-Aschoff sinus (irregularly shaped tubular structures lined by cuboidal lining epithelium with round to oval nucleus) with fibrocollagenous tissue and inflammatory cells (lymphocytes).

Note : All biopsy specimen will be stored for 15 (fifteen) days, block and slides for 5 (five) years only from the time of receipt at the laboratory. No request for any of the above, will be entertained after the due date.

Reference

- i) Rosai and Ackerman's Surgical Pathology.
- ii) Modern Surgical Pathology.

Gulshan Yadav, MD
Consultant Pathologist