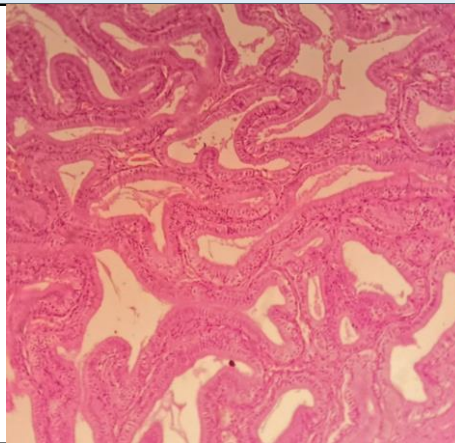


<b>Patient Name</b>	<b>Ms. SHAFEEQA GH NABI</b>	<b>Client Name</b>	Tantray Labs, Jammu &	<b>Specimen Received</b>	03/05/19
<b>Age/Sex</b>	45 Years/Female		Kashmir	<b>Specimen Type</b>	Tissue
<b>Patient ID</b>	011905030423	<b>Client Code</b>	MolQ1849P	<b>Collection Date</b>	03/05/19
<b>Specimen ID</b>	MOLQ/B-776/19			<b>Report Date</b>	07/05/19

## SURGICAL PATHOLOGY REPORT

### Gall Bladder

#### CHOLECYSTITIS AND CHOLELITHIASIS



**SPECIMEN**  
Gall Bladder

**GROSS**  
Received 6.5x2.9 cm long gall bladder. Cut section shows stones.

#### Microscopy

Section examined shows ulcerative mucosa and Rokitansky-Aschoff sinuses (irregularly shaped tubular structures lined by cuboidal lining epithelium with round to oval nucleus) with fibro collagenous tissue and inflammatory cells (lymphocytes).

**Note :** All biopsy specimen will be stored for 15 (fifteen) days, block and slides for 5 (five) years only from the time of receipt at the laboratory. No request for any of the above, will be entertained after the due date.

#### Reference

- i) Rosai and Ackerman's Surgical Pathology.
- ii) Modern Surgical Pathology.

**Gulshan Yadav, MD**  
Consultant Pathologist