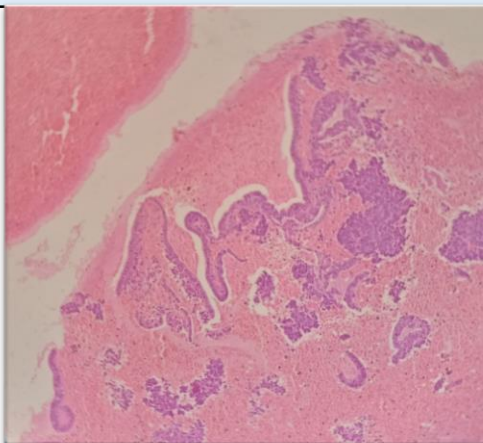


<b>Patient Name</b>	<b>Mrs. NEELAM</b>	<b>Client Name</b>	Uttam Diagnostics, Agra	<b>Specimen Received</b>	03/05/19
<b>Age/Sex</b>	35 Years/Female	<b>Client Code</b>	MolQ1359CM	<b>Specimen Type</b>	Tissue
<b>Patient ID</b>	011905030031			<b>Collection Date</b>	03/05/19
<b>Specimen ID</b>	MOLQ/B-770/19			<b>Report Date</b>	07/05/19

## SURGICAL PATHOLOGY REPORT

### ENDOMETRIUM

#### Proliferative phase



#### SPECIMEN

Endometrium

#### GROSS

Received multiple greyish white tissue piece.

#### Microscopy

Section examined shows endometrial glands having columnar to cuboidal lining epithelium with small round nucleus with squamous metaplasia. Stroma shows mononuclear inflammatory cells.

No granuloma and no malignant cells seen

**Note :** All biopsy specimen will be stored for 15 (fifteen) days, block and slides for 5 (five) years only from the time of receipt at the laboratory. No request for any of the above, will be entertained after the due date.

#### Reference

- i) Rosai and Ackerman's Surgical Pathology.
- ii) Modern Surgical Pathology.

**Gulshan Yadav, MD**  
Consultant Pathologist