

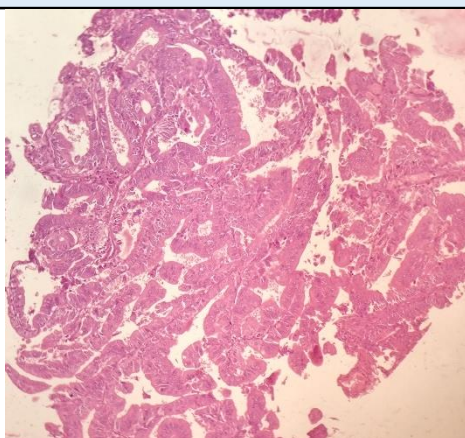
<b>Patient Name</b>	Mr. LALMANI	<b>Client Name</b>	Lifeaid Wellness Centre,	<b>Specimen Received</b>	27-Apr-2019
<b>Age/Sex</b>	72/M		Gurgaon	<b>Specimen Type</b>	Tissue
<b>Patient ID</b>	011904270149	<b>Client Code</b>	MolQ1476CM	<b>Collection Date</b>	27-Apr-2019
<b>Specimen ID</b>	MOLQ/B-730/19	<b>Ref. Doctor</b>		<b>Report Date</b>	10-May-2019

## SURGICAL PATHOLOGY REPORT

Large Abdominal Mass (Overdistended Gall bladder reaching to pelvis with Cholecysto-Pancreato-Fistula)

### DIAGNOSIS

**ADENOCARCINOMA, PREDOMINANTLY PAPILLARY, MODERATELY DIFFERENTIATED. (pTisNxMo)**



#### SPECIMEN

Large Abdominal Mass (Overdistended Gall bladder reaching to pelvis with Cholecysto-Pancreato-Fistula))

#### Microscopy

##### Tumor Site

Fundus

##### Tumor Body

Greatest Dimension: 3x2 cm

##### Histologic Grade

G2: Moderately differentiated

**Lymph Vascular Invasion:** Absent

**Perineural Invasion:** Not identified

##### Pathologic Staging (pTNM)

Primary Tumor (pTis)

Regional Lymph Nodes (pN)

pNX: Cannot be assessed.

#### GROSS

Received 11x10 cm cytic tissue piece. Cut section shows growth measuring 3x2 cm.

**Microscopy:** Malignant tumor arising from overlying mucosa in form of glands and papillae, Tumor cells are round to columnar with pleomorphic nuclei having coarse chromatin and prominent nucleoli. Many mitotic figures are seen. At places lumen of the glands shows neutrophils. Large areas of hemorrhage is seen with chronic inflammation.

**Note :** All biopsy specimen will be stored for 15 (fifteen)days, block and slides for 5(five) years only from the time of receipt at the laboratory.

No request ,for any of the above ,will be entertained after the due date.

#### Reference

- i) Rosai and Ackerman's Surgical Pathology.
- ii) Modern Surgical Pathology.

**Gulshan Yadav, MD**  
Consultant Pathologist