



ECHO REPORT

NAME Ref. No.:	Mr. Dhruv Bhalla	AGE/SEX	31/M
MR. NO	006397	HOSPITAL NO.	OPD
REF. BY	Health Check Up	DATE	03.05.2019

PROCEDURES : M-MODE / 2D / DOPPLER / COLOUR / CONTRAST B.B.A. M2
MEASUREMENTS :

		NORMALS
Aortic Root Diameter	2.9	2.0-3.7 cm < 2.2 cm/M2
Aortic Valve Opening		1.5-2.6 cm
Right Ventricular Dimension		0.7-2.6 cm < 1.4 cm/M2
Right Ventricular Thickness		0.3-0.9 cm
Left Atrial Dimension	3.4	1.9-4.0 cm < 2.2 cm/M2
Left Ventricular ED Dimension	2.9	3.7-5.6 cm < 3.2 cm/M2
Left Ventricular ES Dimension	4.1	2.2-4.0 cm
Interventricular Septal Thickness	0.8ED ES	0.6-1.2 cm
Left Vent PW Thickness	0.7ED ES	0.5-1.0 cm
IVS / LVPW		

INDICES OF LEFT VENT. FUNCTION

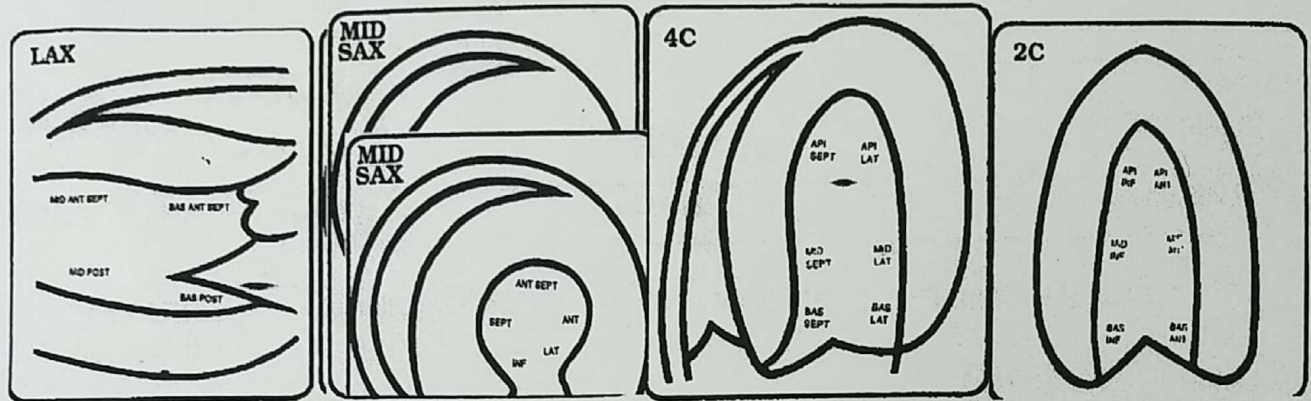
Mitral E-Septal separation		<0.9 cm
Minor axis		24.42%
LV Ejection Fraction	60%	55-65%

IMAGING:

M-Mode examination revealed normal movement of both mitral leaflets during diastole. No SAM or mitral valve prolapse is seen. Aortic cusps are not thickened and closure line is central. Tricuspid valve is normal. Pulmonary valve is normal. Aortic root is normal in size. Dimension of left atrium and left ventricle are normal. No LVH present.

2-D imaging in PLAX, SAX and apical views revealed a normal sized left ventricle. Movement of septum, inferior, anterior, posterior and lateral walls is normal. Global LVEF is **%. Mitral valve opening is normal. No evidence of mitral valve prolapse is seen. Aortic valve has three cusps and its opening is not restricted. Tricuspid valve leaflets move normally. Pulmonary valve is normal. Interatrial and interventricular septa are intact. No intracardiac mass or thrombus is seen. No pericardial pathology is observed.

LV WALL MOTION



DOPPLER

MV	E = cm/sec A = cm/sec	MR	Nil
AV	cm/sec	AR	Nil
TV	cm/sec	TR	Nil
PV	cm/sec	PR	Nil

COLOUR FLOW

Normal colour flow

FINAL DIAGNOSIS:

2D Colour Doppler Exam of Mr. Dhru Bhalla revealed:

1. No regional wall motion abnormalities seen in resting state. LVEF - 60%.
2. No LVH. All cardiac chambers dimensions are normal.
3. All valves are normal.
4. Normal left ventricular systolic function.
5. No diastolic Dysfunction .
6. No intracardiac mass or thrombus
7. No pericardial pathology seen. No clot /veg seen.

DR. ASHISH GUPTA

Dr. ASHISH GUPTA
 MBBS, MD(Medicine), DM(Cardiology)
 Consultant Cardiology
 Vivekanand Arogya Kendra
 Regn. No. HMC-10365