

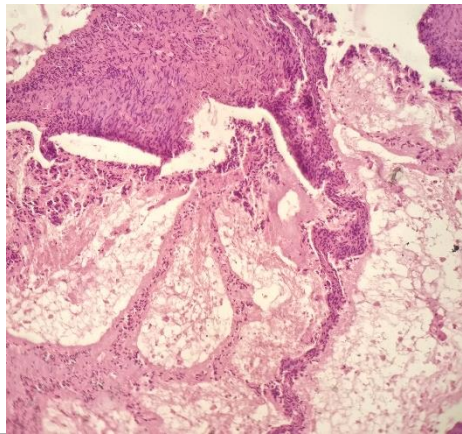
Patient Name	Ms. RAHILA	Client Name	Murad Hospital, Nuh	Specimen Received	02-May-2019
Age/Sex	30 Years/Female	Client Code	MolQ1830P	Specimen Type	Tissue
Patient ID	011905020342	Ref. Doctor		Collection Date	02-May-2019
Specimen ID	MOLQ/B-772-19			Report Date	09-May-2019

SURGICAL PATHOLOGY REPORT

Large Complex Cyst? Malignancy? Tumor?

DIAGNOSIS

BORDERLINE OVARIAN TUMOR



SPECIMEN

Large Complex Cyst? Malignancy?
Tumor?

GROSS

Received 30x35 cm greyish white tissue piece. Cut section shows mucoid material.

Microscopy

1. Section examined shows cuboidal lining epithelium with round nucleus revealing mild anisonucleosis with picket fence appearance.
2. Presence of goblet cells along with ovarian tissue, mucoid areas and hemorrhagic areas are also evident.

Note : All biopsy specimen will be stored for 15 (fifteen)days, block and slides for 5(five) years only from the time of receipt at the laboratory. No request ,for any of the above ,will be entertained after the due date.

Reference

- i) Rosai and Ackerman's Surgical Pathology.
- ii) Modern Surgical Pathology.

Gulshan Yadav, MD
Consultant Pathologist