

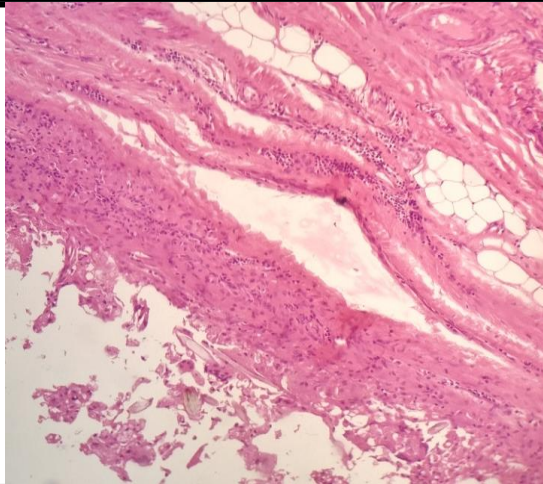
Patient Name	Mrs. SAHIRA	Client Name	Bandipora Collection Centre,	Specimen Received	30/04/19
PAZALPORA			Jammu & Kashmir	Specimen Type	Tissue
Age/Sex	38 Years/Female	Code	MolQ1929P	Collection Date	30/04/19
Patient ID	011904180076	Ref. Doctor	HEALTH CREASENT	Report Date	01/05/19
Specimen ID	MOLQ/B-748/19				

SURGICAL PATHOLOGY REPORT

Bilateral ovary in same contener

DIAGNOSIS

Dermoid cyst and Cystadenoma.



SPECIMEN

Bilateral ovary

GROSS

Received 6x4,4x4cm greyish white tissue piece cut section shows mucoid material with hair And
Other ovary cut section shows cheese and mucoid material.

Microscopy

Section examined shows ovarian tissue cuboidal lining epithelium small round nucleus with hair mature adipose cells.

Other ovary shows ovarian tissue, cuboidal lining epithelium

Note : All biopsy specimen will be stored for 15 (fifteen)days, block and slides for 5(five) years only from the time of receipt at the laboratory. No request ,for any of the above ,will be entertained after the due date.

Reference

- i) Rosai and Ackerman's Surgical Pathology.
- ii) Modern Surgical Pathology.

Gulshan Yadav, MD
Consultant Pathologist