

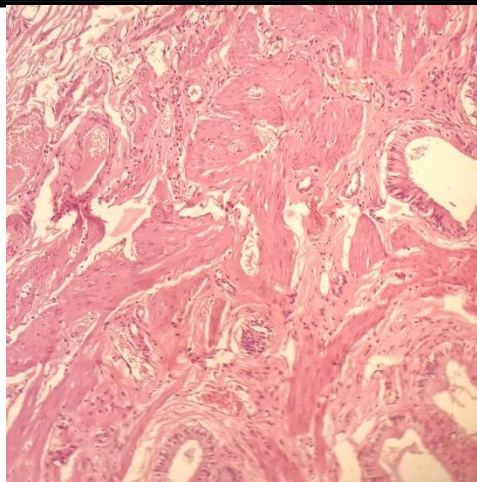
Patient Name	ZAITOONA D/O M	Client Name	Patients Care Clinical	Specimen Received	28/04/2019
Age/Sex	45 YRS/F		Laboratory, Jammu & Kashmir	Specimen Type	Tissue
Patient ID	011904280043	Code		Collection Date	28/04/2019
Specimen ID	MOLQ/B-744/19	Ref. Doctor		Report Date	01/05/2019

SURGICAL PATHOLOGY REPORT

Gall bladder

DIAGNOSIS

CHOLECYSTITIS WITH CHOLELITHIASIS



SPECIMEN
Gall bladder

GROSS
Received 6.5x2.8cm long gall bladder without stones.

Microscopy

Section examined shows ulcerative mucosa and Rokitansky-Aschoff sinus (irregularly shaped tubular structures lined by cuboidal lining epithelium with round to oval nucleus) with fibrocollagenous tissue and inflammatory cells (lymphocytes).

Note : All biopsy specimen will be stored for 15 (fifteen) days, block and slides for 5 (five) years only from the time of receipt at the laboratory. No request, for any of the above, will be entertained after the due date.

Reference

- i) Rosai and Ackerman's Surgical Pathology.
- ii) Modern Surgical Pathology.

Gulshan Yadav, MD
Consultant Pathologist