

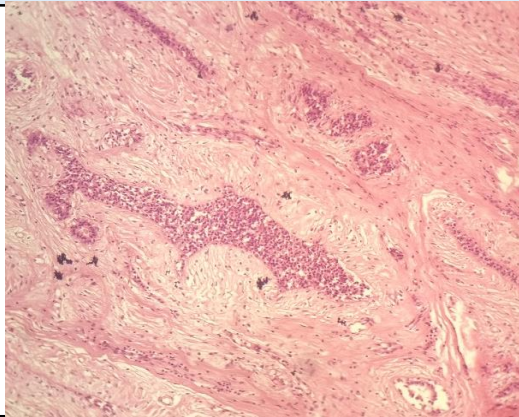
Lipoma

Patient Name	Mr. SAMOON	Client Name	Civil Hospital-P	Specimen Received	27/04/19
Age/Sex	27 Years/Male	Client Code	MolQ1681P	Specimen Type	Tissue
Patient ID	011904270281	Ref. Doctor		Collection Date	27/04/19
Specimen ID	MOLQ/B-733/19			Report Date	30/04/19

SURGICAL PATHOLOGY REPORT Lipoma

DIAGNOSIS

Lipoma



SPECIMEN

Lipoma

GROSS

Received 17x14cm yellowish tissue piece.

Microscopy

Section examined shows mature adipose cells with fibocollagenous tissue and few inflammatory cells. No malignant and no granuloma seen.

Note : All biopsy specimen will be stored for 15 (fifteen)days, block and slides for 5(five) years only from the time of receipt at the laboratory. No request ,for any of the above ,will be entertained after the due date.

Reference

- i) Rosai and Ackerman's Surgical Pathology.
- ii) Modern Surgical Pathology.



Gulshan Yadav, MD
Consultant Pathologist