

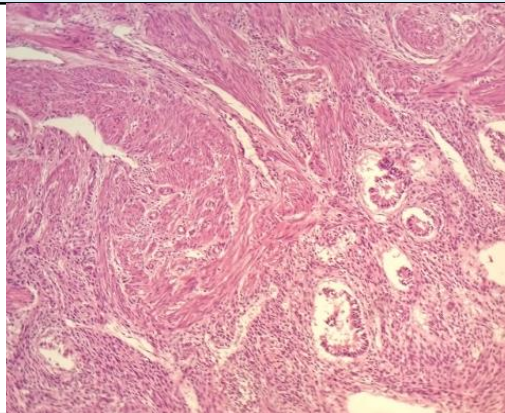
<b>Patient Name</b>	<b>Mr. MASHOOQ</b>	<b>Client Name</b>	Bandipora Collection Centre,	<b>Specimen Received</b>	23/04/19
<b>Age/Sex</b>	12 Years/Male		Jammu & Kashmir	<b>Specimen Type</b>	Tissue
<b>Patient ID</b>	011904230248	<b>Client Code</b>	MolQ1929P	<b>Collection Date</b>	23/04/19
<b>Specimen ID</b>	MOLQ/B-723/19	<b>Ref. Doctor</b>	DR ISHFAQ	<b>Report Date</b>	30/04/19

## SURGICAL PATHOLOGY REPORT

### Rectal polyp

#### DIAGNOSIS

**Inflammatory polyp.**



#### SPECIMEN

Rectal polyp

#### GROSS

Received 1x1cm greyish white tissue piece.

#### Microscopy

- Section examined shows sub mucosal glands having columnar lining epithelium with small round to oval nucleus with inflammatory cells( polymorphs, lymphocyte, plasmacytoid cells and eosinophils).

**Note :** All biopsy specimen will be stored for 15 (fifteen)days, block and slides for 5(five) years only from the time of receipt at the laboratory. No request ,for any of the above ,will be entertained after the due date.

#### Reference

- Rosai and Ackerman's Surgical Pathology.
- Modern Surgical Pathology.

**Gulshan Yadav, MD**  
Consultant Pathologist