

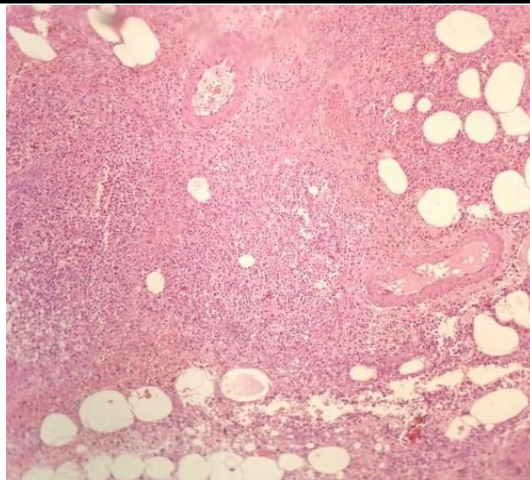
Patient Name	Ms. ANJU	Client Name	Civil Hospital-P	Specimen Received	26/04/2019
Age/Sex	18 Years/Female	Code	MolQ1681P	Specimen Type	Tissue
Patient ID	011904260188	Ref. Doctor	DR ANJU BISNOI	Collection Date	26/04/2019
Specimen ID	MOLQ/B-728/19			Report Date	29/04/2019

SURGICAL PATHOLOGY REPORT

Appendix

DIAGNOSIS

ACUTE APPENDICITIS



SPECIMEN

Appendix

GROSS

Received 5.8x1.2cm long appendix cut section shows fecolith.

Microscopy

Section examined shows lymphoid follicles with ulcerative mucosa. Deeper tissue shows inflammatory cells (polymorphs, lymphocytes and few histiocytes).

Note : All biopsy specimen will be stored for 15 (fifteen)days, block and slides for 5(five) years only from the time of receipt at the laboratory. No request ,for any of the above ,will be entertained after the due date.

Reference

- i) Rosai and Ackerman's Surgical Pathology.
- ii) Modern Surgical Pathology.

Gulshan Yadav, MD
Consultant Pathologist