

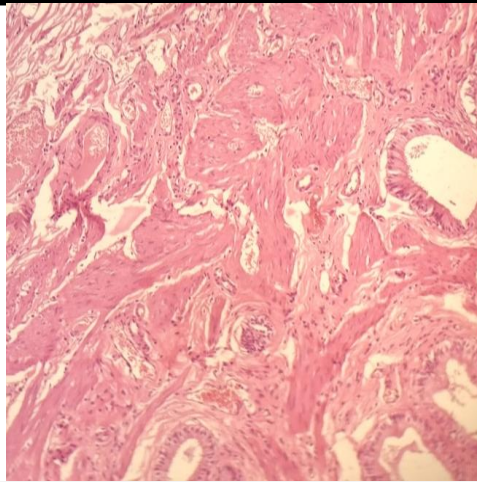
Patient Name	Mrs. FAREEDA	Client Name	Tantray Labs, Jammu & Kashmir	Specimen Received	25/04/2019
Age/Sex	35 Years/Female	Code	MolQ1849P	Specimen Type	Tissue
Patient ID	011904250362	Ref. Doctor		Collection Date	25/04/2019
Specimen ID	MOLQ/B-722/19			Report Date	27/04/2019

SURGICAL PATHOLOGY REPORT

Gall bladder

DIAGNOSIS

CHOLECYSTITIS WITH CHOLELITHIASIS



SPECIMEN
Gall bladder

GROSS
Received 6.5x2.8cm long gall bladder cut section shows stones.

Microscopy

Section examined shows ulcerative mucosa and Rokitansky-Aschoff sinuses (irregularly shaped tubular structures lined by cuboidal lining epithelium with round to oval nucleus) with fibrocollagenous tissue and inflammatory cells (lymphocytes).

Note : All biopsy specimen will be stored for 15 (fifteen) days, block and slides for 5 (five) years only from the time of receipt at the laboratory. No request, for any of the above, will be entertained after the due date.

Reference

- i) Rosai and Ackerman's Surgical Pathology.
- ii) Modern Surgical Pathology.

Gulshan Yadav, MD
Consultant Pathologist