

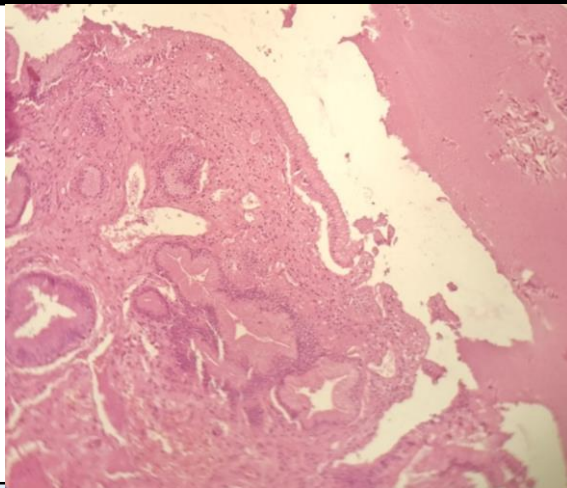
Patient Name	SHABEENA	Client Name	Patients Care Clinical	Specimen Received	25/04/2019
Age/Sex	30 YRS/F		Laboratory, Jammu & Kashmir	Specimen Type	Tissue
Patient ID	011904250091	Code		Collection Date	25/04/2019
Specimen ID	MOLQ/B-721/19	Ref. Doctor	THE PHARMACY	Report Date	27/04/2019

SURGICAL PATHOLOGY REPORT

Gall bladder

DIAGNOSIS

CHOLECYSTITIS WITH CHOLELITHIASIS



SPECIMEN
Gall bladder

GROSS
Received 6.1x2.2cm long gall bladder cut section shows stones.

Microscopy

Section examined shows ulcerative mucosa and Rokitsky Aschoff sinus (irregularly shaped tubular structures lined by cuboidal lining epithelium with round to oval nucleus) with fibro collagenous tissue and inflammatory cells (lymphocytes).

Note : All biopsy specimen will be stored for 15 (fifteen) days, block and slides for 5 (five) years only from the time of receipt at the laboratory. No request, for any of the above, will be entertained after the due date.

Reference

- i) Rosai and Ackerman's Surgical Pathology.
- ii) Modern Surgical Pathology.

Gulshan Yadav, MD
Consultant Pathologist