

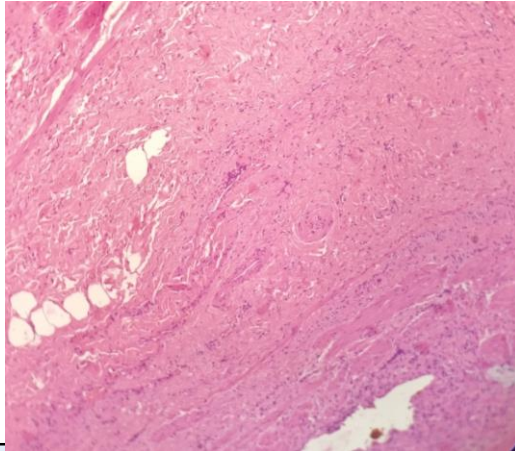
Patient Name /SOPORE	Ms. PARVEENA	Client Name	Bandipora Collection Centre, Jammu & Kashmir	Specimen Received	25/04/2019
Age/Sex	32 Years/Female	Client Code	MolQ1929P	Specimen Type	Tissue
Patient ID	011904230251	Ref. Doctor		Collection Date	25/04/2019
Specimen ID	MOLQ/B-724/19			Report Date	27/04/2019

SURGICAL PATHOLOGY REPORT

Gall bladder

DIAGNOSIS

CHOLECYSTITIS WITH CHOLELITHIASIS



SPECIMEN
Gall bladder

GROSS

Received 5.9x2.2cm long gall bladder cut section shows tiny stones.

Microscopy

- Section examined shows ulcerative mucosa and Rokitansky-Aschoff sinus (irregularly shaped tubular structures lined by cuboidal lining epithelium with round to oval nucleus) with fibrocollagenous tissue and inflammatory cells (lymphocytes).

Note : All biopsy specimen will be stored for 15 (fifteen) days, block and slides for 5 (five) years only from the time of receipt at the laboratory. No request, for any of the above, will be entertained after the due date.

Reference

- Rosai and Ackerman's Surgical Pathology.
- Modern Surgical Pathology.

Gulshan Yadav, MD
Consultant Pathologist