

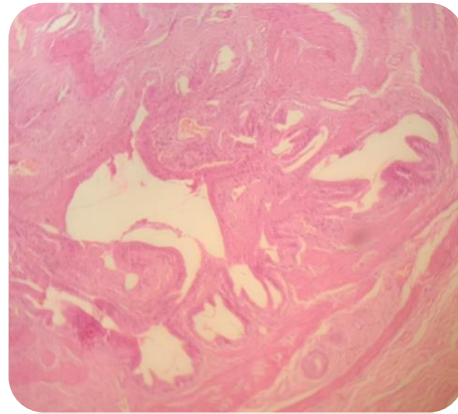
Patient Name Mr. UMA SANKAR	Client Name Chiranjivi Diagnostic Jhars	Specimen Received 23/04/19
Age/Sex 43 Years/Male	Client Code MOLQ1082CM	Specimen Type Tissue
Patient ID 011904230305	Ref. Doctor	Collection Date 23/04/19
Specimen ID MOLQ/B-707/19		Report Date 25/04/19

SURGICAL PATHOLOGY REPORT

Gall bladder

DIAGNOSIS

CHOLECYSTITIS WITH CHOLELITHIASIS



SPECIMEN

Gall bladder

GROSS

Received 5.2x2.7cm long gall bladder cut section shows stones.

Microscopy

section examined shows ulcerative mucosa and rokitansky aschoff sinus (irregularly shaped tubular structures lined by cuboidal lining epithelium with round to oval nucleus) with fibro collagenous tissue and inflammatory cells (lymphocytes).

Note : All biopsy specimen will be stored for 15 (fifteen)days, block and slides for 5(five) years only from the time of receipt at the laboratory. No request ,for any of the above ,will be entertained after the due date.

Reference

- i) Rosai and Ackerman's Surgical Pathology.
- ii) Modern Surgical Pathology. *Report generated at MolQ Laboratory, Gurgaon*

Gulshan Yadav, MD
Consultant Pathologist