

Patient Name	Ms. SUNIL 29466	Client Name	Pushpanjali Hospital	Specimen Received	22/04/19
Age/Sex	51 Years/Female	(Rewari)		Specimen Type	Tissue
Patient ID	011904220256	Client Code	MolQ1789CM	Collection Date	22/04/19
Specimen ID	MOLQ/B-703/19	Ref. Doctor	DR KIRAN	Report Date	26/04/19

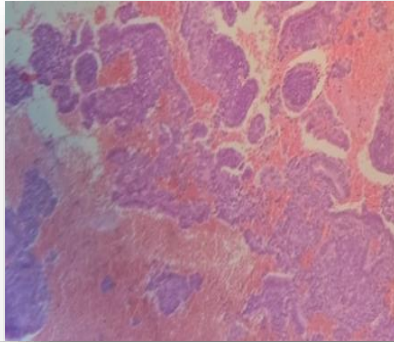
(2)

SURGICAL PATHOLOGY REPORT

Endometrium

DIAGNOSIS

Disordered proliferative phase.



SPECIMEN

Endometrium

GROSS

Received multiple greyish white tissue piece.

Microscopy

Section examined shows small endometrial glands with tortuous endometrial glands. stroma shows mononuclear inflammatory cells.

No granuloma and no malignant cells.

Note : All biopsy specimen will be stored for 15 (fifteen)days, block and slides for 5(five) years only from the time of receipt at the laboratory. No request ,for any of the above ,will be entertained after the due date.

Reference

- i) Rosai and Ackerman's Surgical Pathology.
- ii) Modern Surgical Pathology.

Gulshan Yadav, MD
Consultant Pathologist