

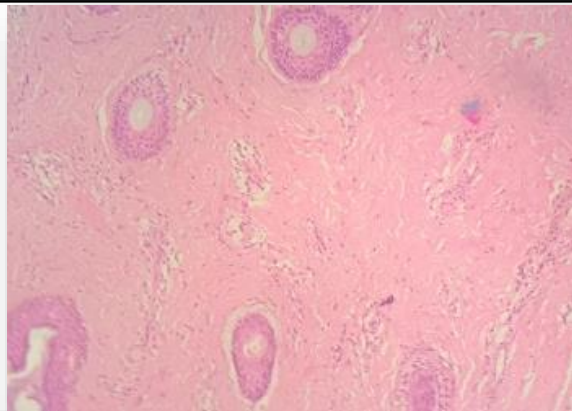
<b>Patient Name</b>	<b>Mr. BASHIR AH BHA</b>	<b>Client Name</b>	Tantray Labs, Jammu &	<b>Specimen Received</b>	21/04/2019
<b>Age/Sex</b>	22 Years/Male		Kashmir	<b>Specimen Type</b>	Tissue
<b>Patient ID</b>	011904210371	<b>Client Code</b>	MolQ1849P	<b>Collection Date</b>	21/04/2019
<b>Specimen ID</b>	MOLQ/B-700/19			<b>Report Date</b>	24/04/2019

## SURGICAL PATHOLOGY REPORT

### Scrotal sebaceous cyst

#### DIAGNOSIS

Suggestive of benign cystic lesion.



#### SPECIMEN

Scrotal sebaceous cyst

#### GROSS

Received 1x1cm greyish white tissue piece.

#### Microscopy

Section examined shows Squamous lining epithelial deeper tissue shows fibro collagenous and calcified tissue and inflammatory cells.

No granuloma and no malignant cells seen.

**Note :** All biopsy specimen will be stored for 15 (fifteen)days, block and slides for 5(five) years only from the time of receipt at the laboratory. No request ,for any of the above ,will be entertained after the due date.

#### Reference

- i) Rosai and Ackerman's Surgical Pathology.
- ii) Modern Surgical Pathology.

**Gulshan Yadav, MD**  
Consultant Pathologist