

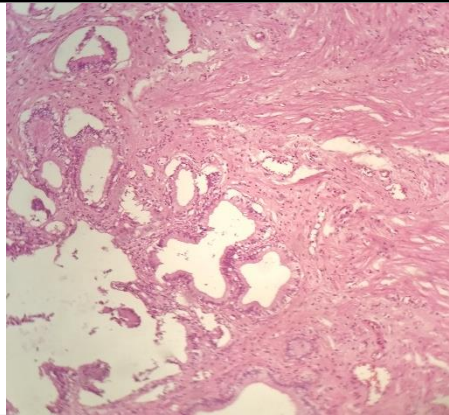
<b>Patient Name</b>	<b>Mrs. APARA BASHIST</b>	<b>Client Name</b>	SBS Diagnostic Centre, Gurgaon	<b>Specimen Received</b>	19-Apr-2019
<b>Age/Sex</b>	33 Years/Female	<b>Client Code</b>	MolQ1325CM	<b>Specimen Type</b>	Tissue
<b>Patient ID</b>	011904190408	<b>Ref. Doctor</b>		<b>Collection Date</b>	19-Apr-2019
<b>Specimen ID</b>	MOLQ/B-683/19			<b>Report Date</b>	22-Apr-2019

## SURGICAL PATHOLOGY REPORT

### GALL BLADDER.

#### DIAGNOSIS

#### CHOLECYSTITIS AND CHOLELITHIASIS



#### SPECIMEN

Gall Bladder.

#### GROSS

Received 6.5x2.8cm long gall bladder cut section shows stones.

#### Microscopy

- Section examined shows ulcerative mucosa and Rokitansky-Aschoff sinuses (irregularly shaped tubular structures lined by cuboidal lining epithelium with round to oval nucleus) with fibro collagenous tissue and inflammatory cells (lymphocytes).

**Note :** All biopsy specimen will be stored for 15 (fifteen) days, block and slides for 5 (five) years only from the time of receipt at the laboratory. No request ,for any of the above will be entertained after the due date.

#### Reference

- Rosai and Ackerman's Surgical Pathology.
- Modern Surgical Pathology.

**Gulshan Yadav, MD  
Consultant Pathologist**