

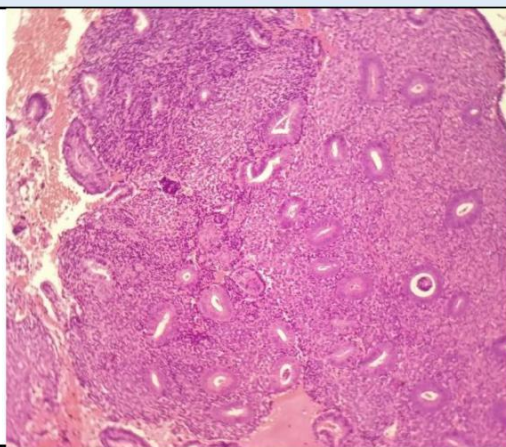
Patient Name	Mrs. NEERA	Client Name	Lalita Memorial Hospital Pvt. Ltd. (Rewari)	Specimen Received	19-Feb-2019
Age/Sex	34 Years/Female	Client Code	MolQ1652P	Specimen Type	Tissue
Patient ID	011904190294	Ref. Doctor		Collection Date	1-Feb-2019
Specimen ID	MOLQ/B-686/19			Report Date	22-Feb-2019

SURGICAL PATHOLOGY REPORT

Endometrium

IMPRESSION

DISORDERED PROLIFERATIVE PHASE



SPECIMEN

Endometrium

GROSS

Received multiple greyish white tissue piece.

Microscopy

1. Section examined shows small and tortuous endometrial glands columnar lining epithelium round to oval nucleus with squamous metaplasia in few glands shows mononuclear inflammatory cells seen.
2. No granuloma and no malignant cells seen.

Note : All biopsy specimen will be stored for 15 (fifteen) days, block and slides for 5 (five) years only from the time of receipt at the laboratory. No request for any of the above, will be entertained after the due date.

Reference

- i) Rosai and Ackerman's Surgical Pathology.
- ii) Modern Surgical Pathology.

Gulshan Yadav, MD
Consultant Pathologist