

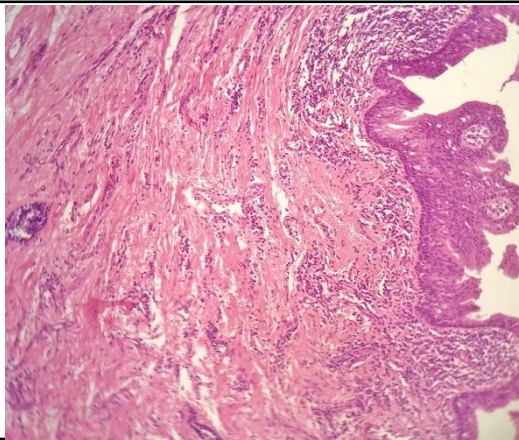
<b>Patient Name</b>	Mrs. PRIYANKA	<b>Client Name</b>	Sona Devi Hospital,	<b>Specimen Received</b>	19-Apr-2019
<b>Age/Sex</b>	23/F		Gurgaon	<b>Specimen Type</b>	Tissue
<b>Patient ID</b>	011904190160	<b>Client Code</b>	MolQ1233P	<b>Collection Date</b>	19-Apr-2019
<b>Specimen ID</b>	MOLQ/B-687-19	<b>Ref. Doctor</b>		<b>Report Date</b>	22-Apr-2019

## SURGICAL PATHOLOGY REPORT

Infected epidermal cyst.

### DIAGNOSIS

**Infected Epidermal Cyst.**



#### SPECIMEN

Infected epidermal cyst.

#### GROSS

Received 1x1cm greyish white tissue piece.

#### Microscopy

1. Section examined shows Squamous lining epithelium having round nucleus with large no of inflammatory cells (polymorph, lymphocyte)

**Note :** All biopsy specimen will be stored for 15 (fifteen)days, block and slides for 5(five) years only from the time of receipt at the laboratory. No request ,for any of the above ,will be entertained after the due date.

#### Reference

- i) Rosai and Ackerman's Surgical Pathology.
- ii) Modern Surgical Pathology.

**Gulshan Yadav, MD**  
Consultant Pathologist