

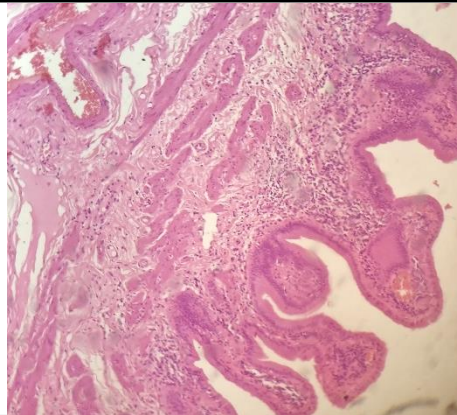
Patient Name	Mr. OM PARKASH	Client Name	Chiranjeev Path Lab,	Specimen Received	19-Apr-2019
Age/Sex	63/M		Gurgaon	Specimen Type	Tissue
Patient ID	011904190159	Client Code	MOLQ1019P	Collection Date	19-Apr-2019
Specimen ID	MOLQ/B-684/19	Ref. Doctor		Report Date	22-Apr-2019

SURGICAL PATHOLOGY REPORT

GALL BLADDER.

DIAGNOSIS

CHOLECYSTITIS AND CHOLELITHIASIS



SPECIMEN

Gall Bladder.

GROSS

Received 6.1x2.2cm long gall bladder already cut open with stones.

Microscopy

- Section examined shows ulcerative mucosa and Rokitansky-Aschoff sinuses (irregularly shaped tubular structures lined by cuboidal lining epithelium with round to oval nucleus) with fibrocollagenous tissue and inflammatory cells (lymphocytes).

Note : All biopsy specimen will be stored for 15 (fifteen) days, block and slides for 5 (five) years only from the time of receipt at the laboratory. No request for any of the above will be entertained after the due date.

Reference

- Rosai and Ackerman's Surgical Pathology.
- Modern Surgical Pathology.

Gulshan Yadav, MD
Consultant Pathologist