

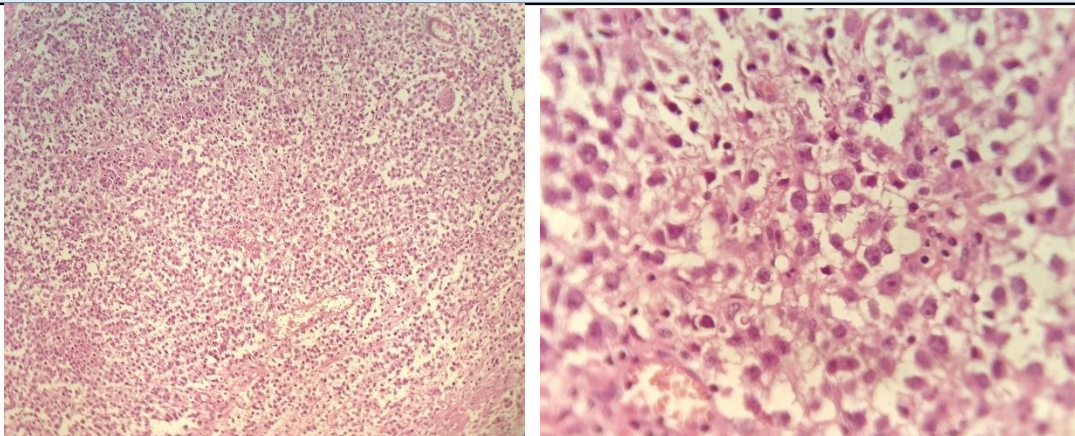
Patient Name	Mr. M.MAQBOOL	Client Name	A-One Collection Centre,	Specimen Received	21-Apr-2019
Age/Sex	60/M		Jammu & Kashmir	Specimen Type	Tissue
Patient ID	041904210011	Client Code	MolQ1767P	Collection Date	21-Apr-2019
Specimen ID	MOLQ/B-702-19	Ref. Doctor		Report Date	22-Apr-2019

SURGICAL PATHOLOGY REPORT

Testis

DIAGNOSIS

SEMINOMA (Classic Type)



SPECIMEN

Testis

GROSS

Received three wax blocks labelled as S 3118 19 (1, 9, 10)

Microscopy

1. Section examined shows sheets of tumor cell, uniformly and variable in size (admixed with medium sized cells (predominantly), few bizzare giant cells and small lymphocytes like cells) having prominent nucleoli and filamentous appearance well separated by fibrocollagenous stroma.
2. Cytoplasm is dense eosinophilic.
3. Presence of lymphocytic infiltration and necrosis within the tumor mass. Mitotic activities are present.

Note : All biopsy specimen will be stored for 15 (fifteen)days, block and slides for 5(five) years only from the time of receipt at the laboratory. No request ,for any of the above ,will be entertained after the due date.

Reference

- i) Rosai and Ackerman's Surgical Pathology.
- ii) Modern Surgical Pathology.

Gulshan Yadav, MD
Consultant Pathologist