

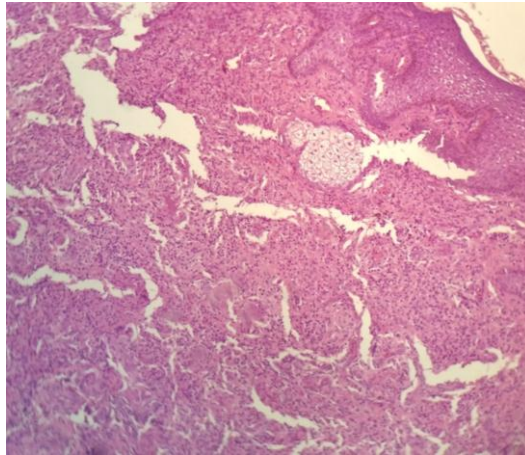
Patient Name	Ms. PRACHI	Client Name	Aravali Hospital	Specimen Received	18/04/2019
Age/Sex	14 YRS/F	Client Code	MolQ1899P	Specimen Type	Tissue
Patient ID	011904180179	Ref. Doctor		Collection Date	18/04/2019
Specimen ID	MOLQ/B-679/19			Report Date	22/04/2019

SURGICAL PATHOLOGY REPORT

Bartholins Cyst

DIAGNOSIS

CHRONIC INFECTIVE CYSTIC LESION.



SPECIMEN

Bartholins Cyst

GROSS

Received multiple greyish white tissue piece.

Microscopy

1. Section examined shows squamous lining epithelium with small round nucleus. Deeper tissue shows fibrocollagenous tissue, blood vessels and large number of inflammatory cells (Lymphocytes, polymorphs and histiocytes).
2. No malignant cells and no granuloma seen.

Note : All biopsy specimen will be stored for 15 (fifteen)days, block and slides for 5(five) years only from the time of receipt at the laboratory. No request ,for any of the above ,will be entertained after the due date.

Reference

- i) Rosai and Ackerman's Surgical Pathology.
- ii) Modern Surgical Pathology.

Gulshan Yadav, MD
Consultant Pathologist