

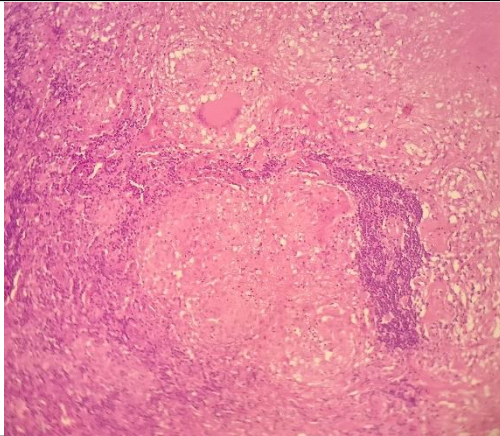
Patient Name	Mr. JITENDER	Client Name	Shri Balaji Multispeciality Hospital	Specimen Received	18-Apr-2019
Age/Sex	22/M		Gurgaon	Specimen Type	Tissue
Patient ID	011904180135	Client Code	MolQ1269CM	Collection Date	18-Apr-2019
Specimen ID	MOLQ/B-680-19	Ref. Doctor		Report Date	22-Apr-2019

SURGICAL PATHOLOGY REPORT

(I) Mesentric Lymph Node
(II) Omentum

DIAGNOSIS

**GRANULOMATOUS REACTION
(TUBERCULAR PATHOLOGY)**



SPECIMEN

(I) Mesentric Lymph Node
(II) Omentum

GROSS

(I) Received 1x1cm greyish white tissue piece.
(II) Received 2.5x2 cm greyish white tissue piece.

Microscopy

(I) Section examined shows lymphoid follicles with epithelioid cells, granuloma formation and caseous necrosis. Section also shows multinucleated giant cells.

(II) Section examined shows mature adipose cells with fibrocollagenous tissue, large number of blood vessels (lymphocyte, polymorphs), epithelioid cells and multinucleated giant cells.

Note : All biopsy specimen will be stored for 15 (fifteen) days, block and slides for 5 (five) years only from the time of receipt at the laboratory. No request, for any of the above, will be entertained after the due date.

Reference

- i) Rosai and Ackerman's Surgical Pathology.
- ii) Modern Surgical Pathology.

**Gulshan Yadav, MD
Consultant Pathologist**