

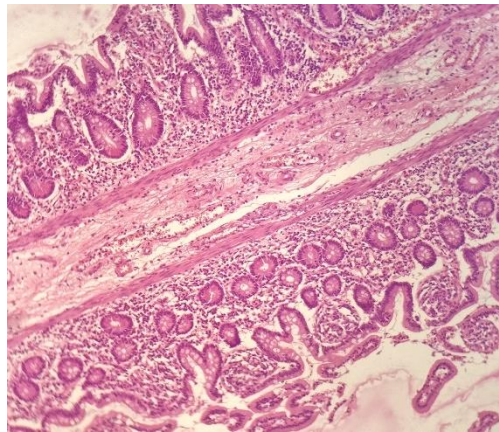
<b>Patient Name</b>	<b>Mr. SATYA PAL 29087</b>	<b>Client Name</b>	Pushpanjali Hospital (Rewari)	<b>Specimen Received</b>	17-Apr-2019
<b>Age/Sex</b>	65/M	<b>Client Code</b>	MolQ1789CM	<b>Specimen Type</b>	Tissue
<b>Patient ID</b>	011904170281	<b>Ref. Doctor</b>	DR.KULDEEP	<b>Collection Date</b>	17-Apr-2019
<b>Specimen ID</b>	MOLQ/B-669-19			<b>Report Date</b>	22-Apr-2019

## SURGICAL PATHOLOGY REPORT

Fecal Peritonitis (Secondary to illeal perforation with stricture ileum ?tubercular) (Part of distal ileum with perforation with stricture attached to mesentery with mesenteric lymph nodes)

### DIAGNOSIS

**PERFORATED WITH ILLEUM WITH NON-SPECIFIC INFLAMMATION AND REACTIVE LYMPHADENITIS.**



#### SPECIMEN

Fecal Peritonitis (Secondary to illeal perforation with stricture ileum ?tubercular) (Part of distal ileum with perforation with stricture attached to mesentery with mesenteric lymph nodes)

#### GROSS

Received 30x3 cm bowel with mesentery with 4x2 cm and 2x2 cm bowel. Perforation of 1.5x0.5 cm present in the mid portion.

#### Microscopy

(I) Proximal End + Distal End + Stricture + Midportion: Section examined shows villi with columnar lining epithelium with round to oval nucleus with submucosal glands with muscularis mucosa and mononuclear inflammatory cells. No granuloma and no malignant cells seen.

(II) Perforation: Section examined shows ulcerative mucosa with columnar lining epithelium. Section also shows large number of blood vessels.

(III) Lymph Nodes: Reactive Lymphadenitis.

**Note :** All biopsy specimen will be stored for 15 (fifteen)days, block and slides for 5(five) years only from the time of receipt at the laboratory. No request ,for any of the above ,will be entertained after the due date.

#### Reference

- i) Rosai and Ackerman's Surgical Pathology.
- ii) Modern Surgical Pathology.

**Gulshan Yadav, MD**  
Consultant Pathologist