

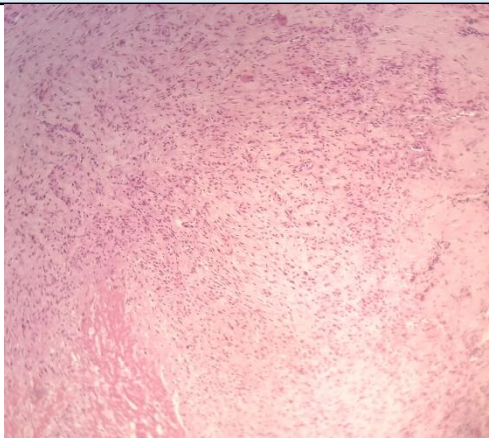
<b>Patient Name</b>	Ms. NIVEDITA	<b>Client Name</b>	North Delhi Diagnostic,	<b>Specimen Received</b>	14-Apr-2019
<b>Age/Sex</b>	15/F		New Delhi	<b>Specimen Type</b>	Tissue
<b>Patient ID</b>	011904140182	<b>Client Code</b>	MolQ1219P	<b>Collection Date</b>	14-Apr-2019
<b>Specimen ID</b>	MOLQ/B-651-19	<b>Ref. Doctor</b>		<b>Report Date</b>	22-Apr-2019

## SURGICAL PATHOLOGY REPORT

Cyst (Right Hand Little Finger)

### DIAGNOSIS

### PIGMENTED VILLONODULAR SYNOVITIS



#### SPECIMEN

Cyst (Right Hand Little Finger)

#### GROSS

Received autolyzed two greyish white tissue piece measuring 1x1 cm in aggregate.

#### Microscopy

- Section examined shows fibrocollagenous tissue with melanin pigmentation and spindle cells with plump nucleus arranged in fascicles.
- No granuloma and no malignant cells seen.

**Note :** All biopsy specimen will be stored for 15 (fifteen)days, block and slides for 5(five) years only from the time of receipt at the laboratory. No request ,for any of the above ,will be entertained after the due date.

#### Reference

- Rosai and Ackerman's Surgical Pathology.
- Modern Surgical Pathology.

**Gulshan Yadav, MD**  
Consultant Pathologist