

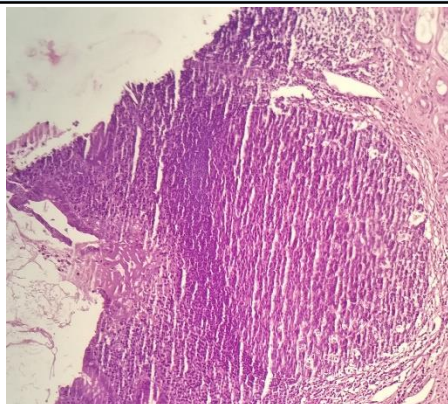
Patient Name	Mrs. SAVITRI DEVI	Client Name	Prakash Hospital	Specimen Received	17/04/2019
Age/Sex	36 Years/Female	Client Code	MolQ1672CM	Specimen Type	Tissue
Patient ID	011904170310	Ref. Doctor		Collection Date	17/04/2019
Specimen ID	MOLQ/664/19(2)			Report Date	20/04/2019

SURGICAL PATHOLOGY REPORT

Intestinal tissue

DIAGNOSIS

Reactive lymphadenitis.



SPECIMEN

Intestinal tissue

GROSS

Received 5x2cm greyish white tissue piece cut section shows intestinal mucosa. No growth.

Microscopy

1. Section examined shows distal end mucoasal lining epithelium columnar lining round to oval submucosal glands.
2. Section examined shows proximal end mucoasal lining epithelium columnar lining round to oval submucosal glands.
3. No granuloma and no malignant cells seen.

Note : All biopsy specimen will be stored for 15 (fifteen)days, block and slides for 5(five) years only from the time of receipt at the laboratory. No request ,for any of the above ,will be entertained after the due date.

Reference

- i) Rosai and Ackerman's Surgical Pathology.
- ii) Modern Surgical Pathology. *Report generated at MolQ Laboratory, Gurgaon*

Gulshan Yadav, MD
Consultant Pathologist