

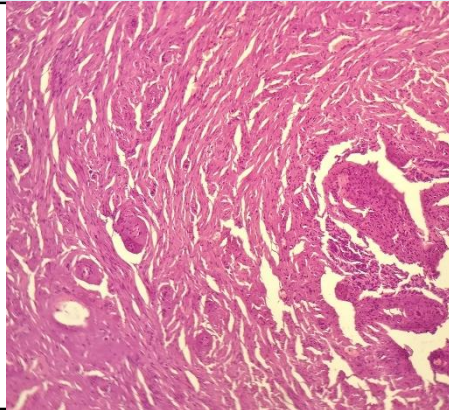
Patient Name	Ms. VIMALA 28485	Client Name	Pushpanjali Hospital (Rewari)	Specimen Received	17/04/2019
Age/Sex	47 Years/Female	Client Code	MolQ1789CM	Specimen Type	Tissue
Patient ID	011904170278	Ref. Doctor	DR.KIRAN	Collection Date	17/04/2019
Specimen ID	MOLQ/B-670/19			Report Date	20/04/2019

SURGICAL PATHOLOGY REPORT

Uterus

DIAGNOSIS

Leiomyoma



SPECIMEN

Uterus

Microscopy

Section examined shows

1. Endometrial with proliferative phase.
2. Myometrium with superficial adenomyosis.
3. Cervix with mononuclear inflammatory cells seen.
4. Fibroid with interlacing muscle bundles.
5. Bilateral tubes confirmed and unremarkable.

Note : All biopsy specimen will be stored for 15 (fifteen) days, block and slides for 5 (five) years only from the time of receipt at the laboratory. No request, for any of the above, will be entertained after the due date.

GROSS

Received 11x4.8cm uterus with cervix cut section shows multiple fibroids 2x2.5, 1x1cm cm with bilateral tubes.

Reference

- i) Rosai and Ackerman's Surgical Pathology.
- ii) Modern Surgical Pathology. *Report generated at MolQ Laboratory, Gurgaon*

Gulshan Yadav, MD
Consultant Pathologist