

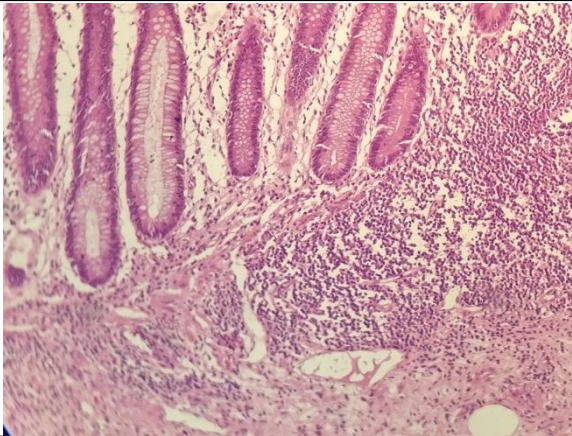
<b>Patient Name</b>	<b>Mr. NITESH</b>	<b>Client Name</b>	Chiranjeev Path Lab	<b>Specimen Received</b>	17/04/2019
<b>Age/Sex</b>	33 Years/Male	<b>Client Code</b>	MOLQ1019P	<b>Specimen Type</b>	Tissue
<b>Patient ID</b>	011904170217	<b>Ref. Doctor</b>		<b>Collection Date</b>	17/04/2019
<b>Specimen ID</b>	MOLQ/B-671/19			<b>Report Date</b>	20/04/2019

## SURGICAL PATHOLOGY REPORT

### Appendix

#### DIAGNOSIS

#### ACUTE APPENDICITIS



#### SPECIMEN

Appendix

#### GROSS

Received 7x1.2cm long appendix.

#### Microscopy

1. Section examined shows lymphoid follicles with ulcerative mucosa. Deeper tissue shows inflammatory cells (polymorphs, lymphocytes and few histiocytes).

**Note :** All biopsy specimen will be stored for 15 (fifteen)days, block and slides for 5(five) years only from the time of receipt at the laboratory. No request ,for any of the above ,will be entertained after the due date.

#### Reference

- i) Rosai and Ackerman's Surgical Pathology.
- ii) Modern Surgical Pathology. *Report generated at MolQ Laboratory, Gurgaon*

**Gulshan Yadav, MD**  
**Consultant Pathologist**