

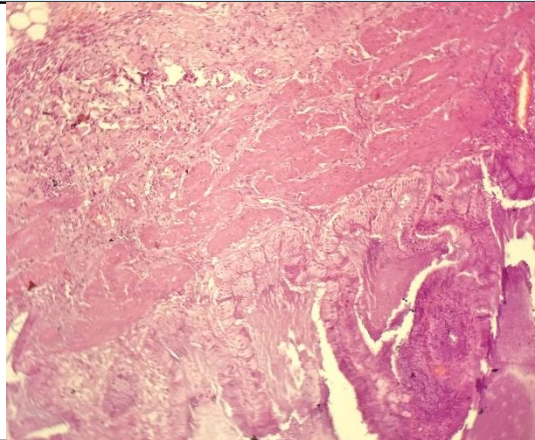
Patient Name	Mr. TINU	Client Name	Path Star Diagnostic	Specimen Received	17/04/2019
Age/Sex	35 Years/Male	Client Code	MOLQ1098CM	Specimen Type	Tissue
Patient ID	011904170210	Ref. Doctor		Collection Date	17/04/2019
Specimen ID	MOLQ/B-672/19			Report Date	20/04/2019

SURGICAL PATHOLOGY REPORT

Gall bladder

DIAGNOSIS

CHOLECYSTITIS WITH CHOLELITHIASIS



SPECIMEN

Gall bladder

GROSS

Received 9x3cm long gall bladder cut section shows stones.

Microscopy

1. Section examined shows ulcerative mucosa and Rokitansky-Aschoff sinuses (irregularly shaped tubular structures lined by cuboidal lining epithelium with round to oval nucleus) with fibrocollagenous tissue and inflammatory cells (lymphocytes).

2.

Note : All biopsy specimen will be stored for 15 (fifteen) days, block and slides for 5 (five) years only from the time of receipt at the laboratory. No request, for any of the above, will be entertained after the due date.

Reference

- i) Rosai and Ackerman's Surgical Pathology.
- ii) Modern Surgical Pathology. *Report generated at MolQ Laboratory, Gurgaon*

Gulshan Yadav, MD
Consultant Pathologist