

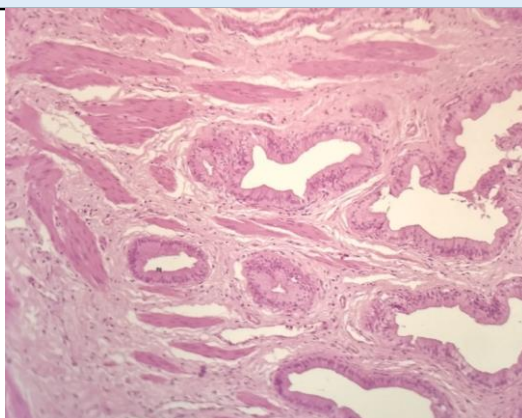
Patient Name	Mr. KRISHAN	Client Name	Sona Devi Hospital	Specimen Received	17/04/2019
Age/Sex	50 Years/Male	Client Code	MolQ1233P	Specimen Type	Tissue
Patient ID	011904170101	Ref. Doctor		Collection Date	17/04/2019
Specimen ID	MOLQ/B-673/19			Report Date	20/04/2019

SURGICAL PATHOLOGY REPORT

Gall bladder

DIAGNOSIS

CHOLECYSTITIS WITH CHOLELITHIASIS



SPECIMEN

Gall bladder

GROSS

Received 6.5x3.2cm long gall bladder cut section show with tiny stones. with bilateral tubes.

Microscopy

- Section examined shows ulcerative mucosa and rokitansky aschoff sinus (irregularly shaped tubular structures lined by cuboidal lining epithelium with round to oval nucleus) with fibro collagenous tissue and inflammatory cells (lymphocytes).

Note : All biopsy specimen will be stored for 15 (fifteen)days, block and slides for 5(five) years only from the time of receipt at the laboratory. No request ,for any of the above ,will be entertained after the due date.

Reference

- Rosai and Ackerman's Surgical Pathology.
- Modern Surgical Pathology. *Report generated at MolQ Laboratory, Gurgaon*

Gulshan Yadav, MD
Consultant Pathologist