

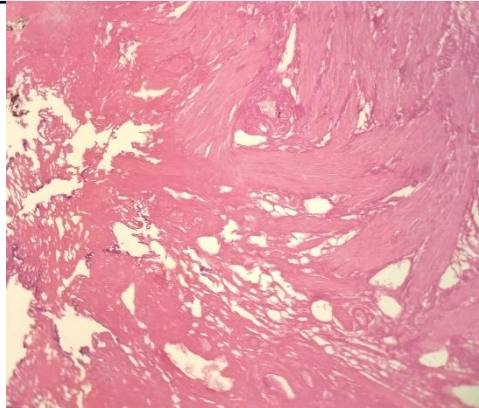
<b>Patient Name</b>	<b>Ms. RUKAYA</b>	<b>Client Name</b>	Bandipora Collection	<b>Specimen Received</b>	17/04/2019
<b>Age/Sex</b>	70 Years/Female		Centre, Jammu & Kashmir	<b>Specimen Type</b>	Tissue
<b>Patient ID</b>	011904170069	<b>Client Code</b>	MolQ1929P	<b>Collection Date</b>	17/04/2019
<b>Specimen ID</b>	MOLQ/B-663/19	<b>Ref. Doctor</b>		<b>Report Date</b>	19/04/2019

## SURGICAL PATHOLOGY REPORT

Gall bladder

### DIAGNOSIS

**CHOLECYSTITIS WITH CHOLELITHIASIS**



#### SPECIMEN

Gall bladder

#### GROSS

Received autolyzed 6.9x2.8cm long gall bladder .

#### Microscopy

- Section examined shows autolyzed changes ulcerative mucosa and rokitansky aschoff sinus (irregularly shaped tubular structures lined by cuboidal lining epithelium with round to oval nucleus) with fibro collagenous tissue and inflammatory cells (lymphocytes).

**Note :** All biopsy specimen will be stored for 15 (fifteen)days, block and slides for 5(five) years only from the time of receipt at the laboratory. No request ,for any of the above ,will be entertained after the due date.

#### Reference

- Rosai and Ackerman's Surgical Pathology.
- Modern Surgical Pathology. *Report generated at MolQ Laboratory, Gurgaon*

**Gulshan Yadav, MD**  
**Consultant Pathologist**