

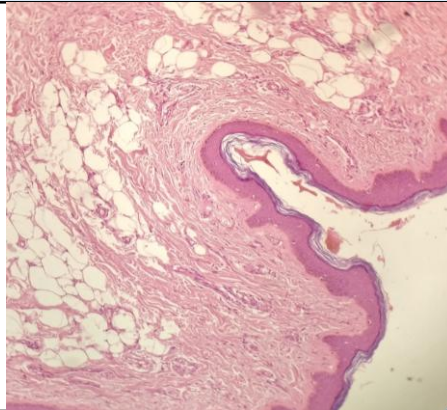
<b>Patient Name</b>	MAHESH S/O PHOOL SINGH	<b>Client Name</b>	Civil Hospital Sec-10	<b>Specimen Received</b>	15/04/2019
<b>Age/Sex</b>	45 YRS/M	<b>Client Code</b>		<b>Specimen Type</b>	Tissue
<b>Patient ID</b>	011904160428	<b>Ref. Doctor</b>		<b>Collection Date</b>	15/04/2019
<b>Specimen ID</b>	MOLQ/B-658/19			<b>Report Date</b>	19/04/2019

## SURGICAL PATHOLOGY REPORT

Giant papilloma

### DIAGNOSIS

**Benign mesenchymal lesion**



#### SPECIMEN

Giant papilloma

#### GROSS

Received 1x1cm greyish white tissue piece.

#### Microscopy

- Section examined shows Squamous lining epithelium with mild hyperkeratosis deeper tissue shows fibro collagenous tissue, blood vessels mature adipose cells.

**Note :** All biopsy specimen will be stored for 15 (fifteen)days, block and slides for 5(five) years only from the time of receipt at the laboratory. No request ,for any of the above ,will be entertained after the due date.

#### Reference

- Rosai and Ackerman's Surgical Pathology.
- Modern Surgical Pathology. *Report generated at MolQ Laboratory, Gurgaon*

**Gulshan Yadav, MD**  
Consultant Pathologist