

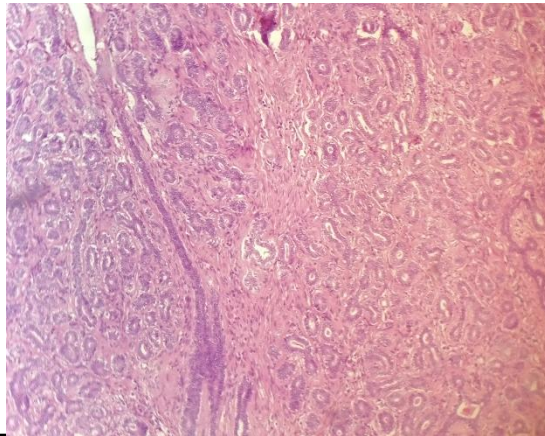
Patient Name	Miss. VERSHA	Client Name	Civil Hospital-P	Specimen Received	15/04/2019
Age/Sex	14 Years/Female	Client Code	MolQ1681P	Specimen Type	Tissue
Patient ID	011904150325	Ref. Doctor		Collection Date	15/04/2019
Specimen ID	MOLQ/B-657/19			Report Date	19/04/2019

SURGICAL PATHOLOGY REPORT

Breast Fibroadenoma

DIAGNOSIS

FIBROADENOMA



SPECIMEN

Breast Fibroadenoma

GROSS

Received 3.2x2.9cm greyish tissue piece well encapsulated.

Microscopy

Section examined shows cystically dilated ducts with cuboidal epithelium with small round nucleus surrounded by fibro collagenous tissue. No granuloma seen.

No malignant cells seen.

Note : All biopsy specimen will be stored for 15 (fifteen)days, block and slides for 5(five) years only from the time of receipt at the laboratory. No request ,for any of the above ,will be entertained after the due date.

Reference

- i) Rosai and Ackerman's Surgical Pathology.
- ii) Modern Surgical Pathology. *Report generated at MolQ Laboratory, Gurgaon*

Gulshan Yadav, MD
Consultant Pathologist