

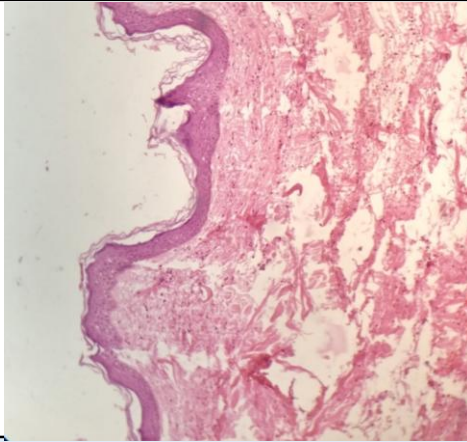
Patient Name	SANJAY SHUKLA	Client Name	Aravali Hospital	Specimen Received	15/04/2019
Age/Sex	38 YRS/M	Client Code		Specimen Type	Tissue
Patient ID	011904150288	Ref. Doctor		Collection Date	15/04/2019
Specimen ID	MOLQ/B-656/19			Report Date	19/04/2019

SURGICAL PATHOLOGY REPORT

Left arm pit polyp

DIAGNOSIS

Benign mesenchymal lesion.



SPECIMEN

Left arm pit polyp

GROSS

Received 3.2x2.8cm greyish white tissue piece.
Fibroid shows 3x2 cm.

Microscopy

1. Section examined shows Squamous lining epithelium deeper tissue shows fibro collagenous tissue, mature adipose cells and blood vessels.
2. No granuloma and no malignant cells seen.

Note : All biopsy specimen will be stored for 15 (fifteen)days, block and slides for 5(five) years only from the time of receipt at the laboratory. No request ,for any of the above ,will be entertained after the due date.

Reference

- i) Rosai and Ackerman's Surgical Pathology.
- ii) Modern Surgical Pathology. *Report generated at MolQ Laboratory, Gurgaon*

Gulshan Yadav, MD
Consultant Pathologist