

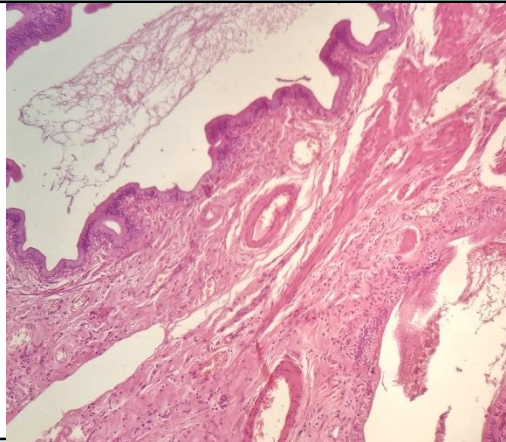
Patient Name	Ms. REHANA 8519	Client Name	Patients Care Clinical	Specimen Received	16/04/2019
Age/Sex	35 Years/Female		Laboratory, Jammu & Kashmir	Specimen Type	Tissue
Patient ID	011904140224	Client Code	MolQ1839P	Collection Date	16/04/2019
Specimen ID	MOLQ/B-661/19	Ref. Doctor	LIFE CARE DOORU	Report Date	19/04/2019

SURGICAL PATHOLOGY REPORT

Gall bladder

DIAGNOSIS

CHOLECYSTITIS WITH CHOLELITHIASIS



SPECIMEN

Gall bladder

GROSS

Received 6.5x2.8cm long gallbladder cut section shows stones.

Microscopy

- Section examined shows ulcerative mucosa and Rokitansky Aschoff sinuses (irregularly shaped tubular structures lined by cuboidal lining epithelium with round to oval nucleus) with fibrocollagenous tissue and inflammatory cells (lymphocytes).

Note : All biopsy specimen will be stored for 15 (fifteen) days, block and slides for 5 (five) years only from the time of receipt at the laboratory. No request, for any of the above, will be entertained after the due date.

Reference

- Rosai and Ackerman's Surgical Pathology.
- Modern Surgical Pathology. Report generated at MolQ Laboratory, Gurgaon

Gulshan Yadav, MD
Consultant Pathologist